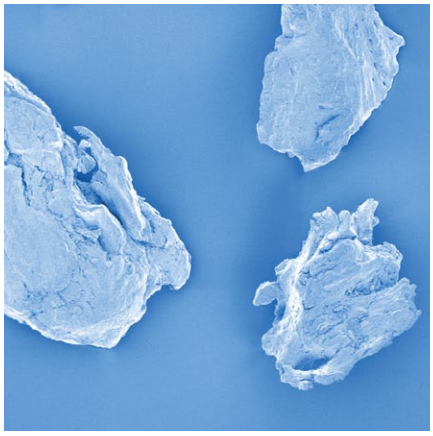
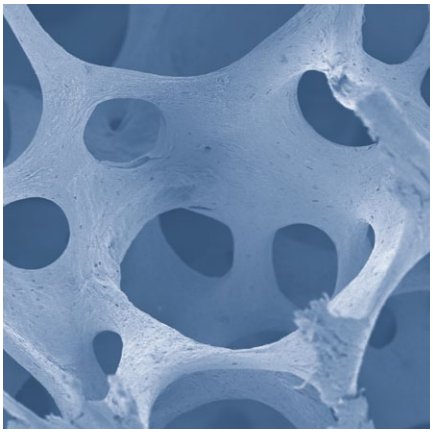
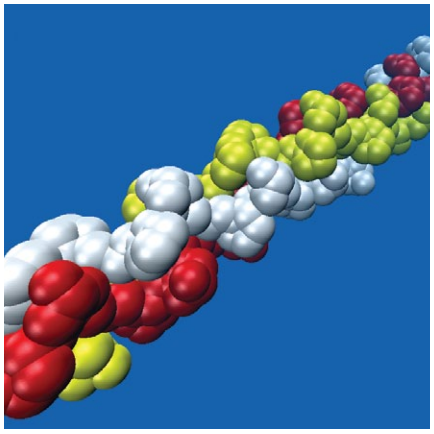
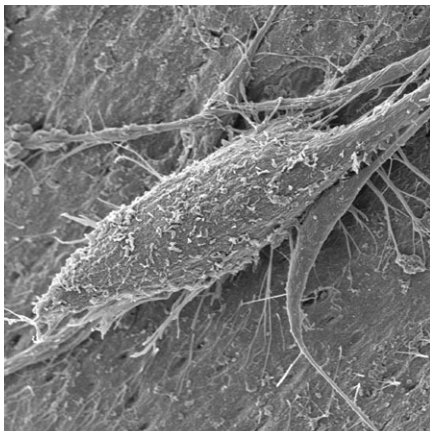
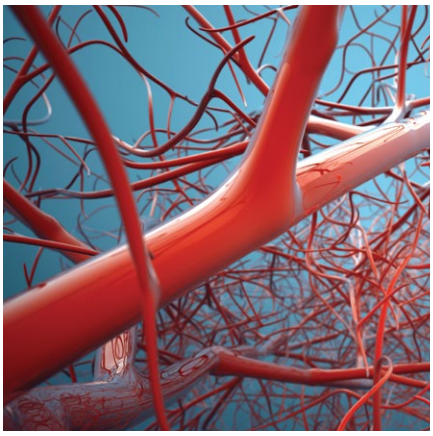
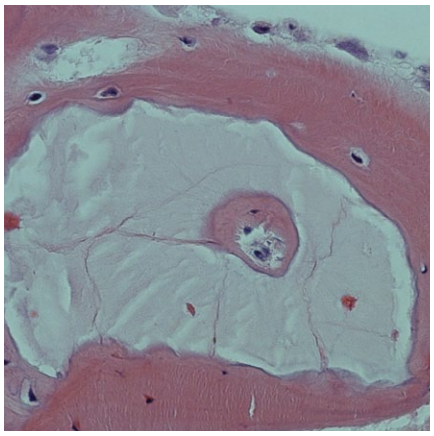

SCIENTIFIC ABSTRACTS

INTERNATIONAL PUBLICATIONS ON OSTEOBIOL® BIOMATERIALS

OsteoBiol®
by Tecnoss

REGENERATION SCIENCE

INSPIRED BY NATURE

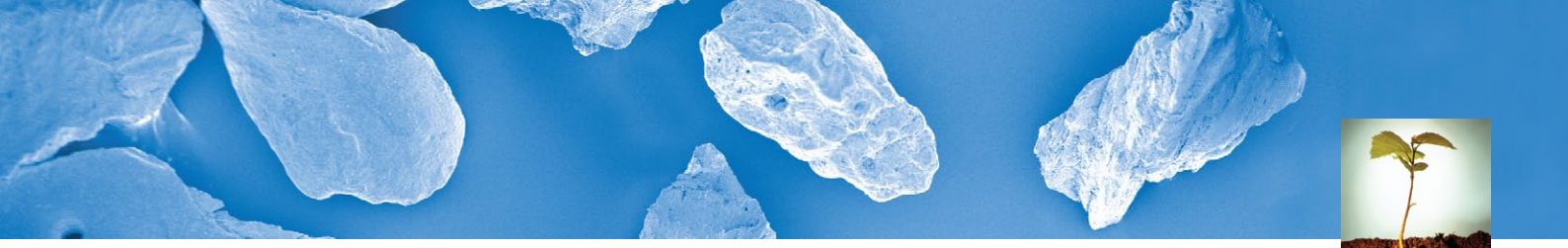

Alveolar regeneration

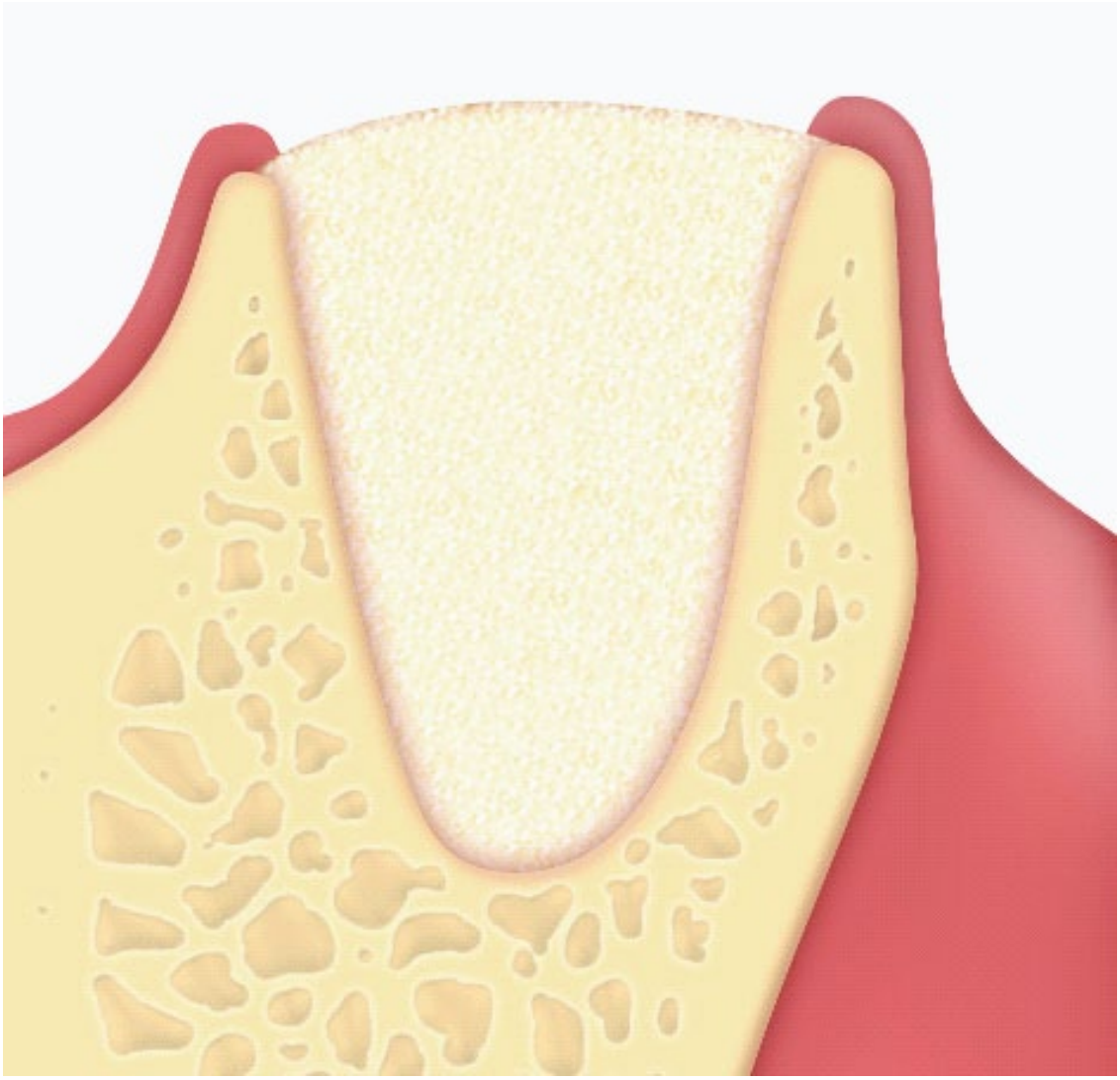

OsteoBiol®
by Tecnoss

REGENERATION SCIENCE

INSPIRED BY NATURE

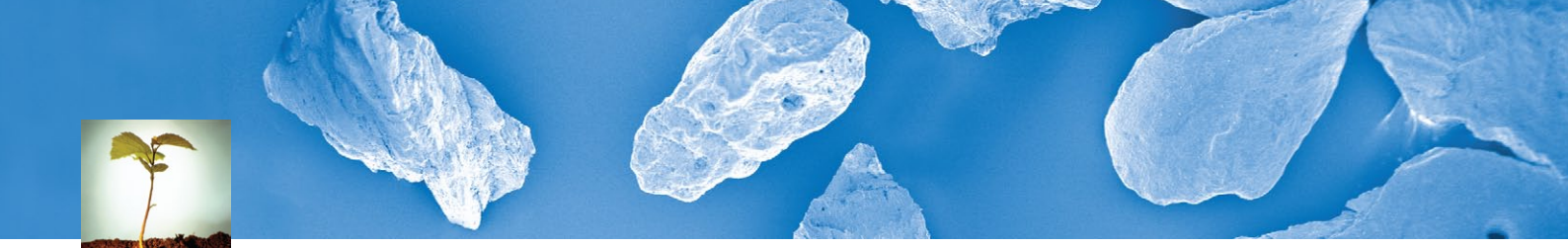

OsteoBiol® by Tecnoss

ALVEOLAR REGENERATION

050

Porcine-derived xenograft combined with a soft cortical membrane versus extraction alone for implant site development: a clinical study in humans

VM Festa[1]
F Addabbo[1]
L Laino[1]
F Femiano[1]
R Rullo[1]

1 | Stomatology Department, Second University of Naples (SUN), Naples, Italy

ORIGINAL ARTICLE
Clinical Implant Dentistry and Related Research
2013 Oct;15(5):707-13

ABSTRACT

Following a tooth extraction, there is a significant reabsorption of the alveolar ridge with quantitative and qualitative changes of its profile. Often, the reabsorption is more pronounced on the buccal aspect of the ridge than on its lingual/palatal counterpart, with dimensional changes in size and shape. In this article, the Authors report the results of a study performed on 15 patients who required double extraction of contralateral premolars and delayed implant placement who were randomly selected to receive alveolar ridge preservation (ARP) procedure compared with extraction alone (EXT). In this split-mouth study, the test sites (ARP) included 15 sockets treated according to the GBR principle for the ARP procedure with a cortico-cancellous porcine bone xenograft in combination with a soft cortical membrane. The xenogenic bone substitute consisted of cortico-cancellous porcine bone (OsteoBiol® *Gen-Os*®, Tecnoss®, Giaveno, Italy) in the form of mixed granules with a diameter ranging from 250 to 1000 μm. The membrane was a soft cortical lamina (OsteoBiol® *Lamina*, Tecnoss®) with a porcine bone origin and a plastic consistency. Horizontal and vertical ridge dimensions were recorded at baseline and 6 months after extractions. After 6 months of healing, it was possible to place implants in all sockets, although some EXT sites had a slight buccal dehiscence requiring bone regeneration procedures after implant insertion. The use of porcine-derived xenograft as intrasocket graft combined with a membrane reduced significantly the bone loss: the mean width for the ARP sites showed a reduction of 1,8±1,3 mm versus a reduction of 3,7±1,2 mm for the EXT sites. Moreover, a significant vertical reduction was demonstrated in the EXT sites for mid-buccal and mid-palatal/lingual measurements (3,1±1,3 mm and 2,4±1,6 mm respectively), whereas in the ARP sites the ridge height remained relatively unchanged (0,6±1,4 and 0,5±1,3 mm).

CONCLUSIONS

Based on the results of this study, the Authors concluded that *"it must be considered that the use of a xenograft in combination with a membrane reduces buccal reabsorption in a ridge crest, which naturally tends to a more palatal/lingual position following tooth extraction, thus decreasing possibility of dehiscence and favoring an ideal implant placement. The ARP approach using porcine bone in combination with a soft cortical membrane significantly limited the bone dimensional changes after tooth extraction when compared with EXT. Therefore, even if some EXT sites allowed an implant placement, the most predictable maintenance of the horizontal and vertical ridge dimensions was achieved only with the ARP procedure"*.

Grafted with

BONE SUBSTITUTE
OsteoBiol® *Gen-Os*

BARRIER -
BONE SUBSTITUTE
OsteoBiol® *Lamina*

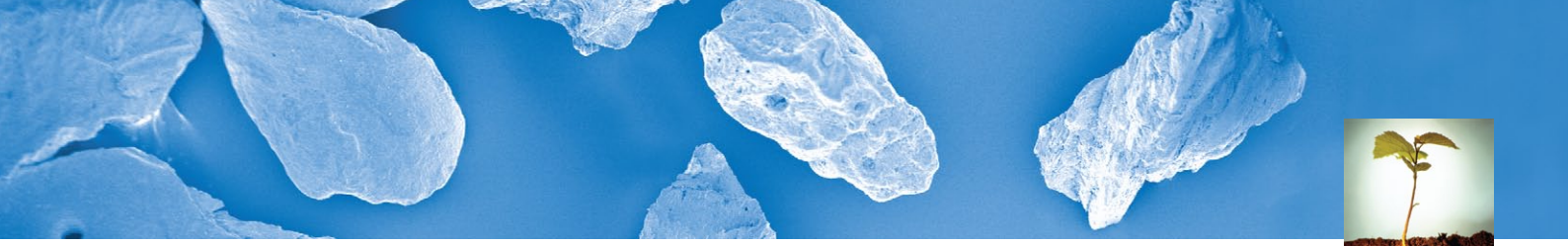

OsteoBiol® by Tecnoss

Molecular, cellular and pharmaceutical aspects of filling biomaterials during the management of extraction sockets

F Alfonsi[1]
V Borgia[2]
G Iezzi[3]
A Piattelli[3]
U Covani[2]
P Tonelli[1]
A Barone[2]

1 | Department of Public Health, Section of Dentistry, University of Florence, Florence, Italy
2 | Unit of Oral Surgery and Implantology, School of Dental Medicine, Department of Surgery, University of Geneve, Switzerland
3 | Department of Medical, Oral and Biotechnological Sciences, Dental School, University G. D'Annunzio of Chieti-Pescara, Chieti, Italy

ABSTRACT

After a tooth extraction, both hard and soft tissues undergo dimensional changes and the aim of grafting and/or guided bone regeneration procedures is to counteract these changes by using different biomaterials and surgical techniques. In this article, the Authors reviewed the clinical, histological, volumetric and molecular results reported in different studies, so to evaluate which are the best surgical techniques and biomaterials for ridge preservation procedures.
Among the biomaterials tested for bone augmentation procedures, the one made of cortico-cancellous granules of porcine bone showed to be very similar to human mineral bone. Its natural micro-porous consistency is supposed to facilitate new bone tissue formation in defect sites and accelerate the regeneration process. Moreover, the studies evaluated in this review reported that this biomaterial is gradually resorbable and able to preserve the original graft shape and volume (osteoconductive property). Other important observations about porcine bone are related to the integration of collagenated porcine bone graft with the new bone and its capability to support the new bone formation when used in extraction sockets. Among the advantages of porcine bone, osteoconductivity and absence of adverse reaction and inflammatory response were mentioned. The histomorphometrical analysis of the reviewed studies showed that the percentage of new bone tissue was 22.5% of the total bone.

CONCLUSIONS

In their review, the Authors pointed out that cortico-cancellous porcine bone satisfied the characteristics of osteoconductivity and volume maintenance during the healing period, allowing new bone formation and reabsorption of the xenograft, without any signs of inflammatory cells.

ORIGINAL ARTICLE
Current Pharmaceutical Biotechnology
2017;18(1):64-75

Grafted with

BONE SUBSTITUTE
OsteoBiol® *Gen-Os®*
OsteoBiol® *mp3®*
OsteoBiol® *Apatos*

MEMBRANE
OsteoBiol® *Evolution*

BARRIER - BONE SUBSTITUTE
OsteoBiol® *Lamina*

PAG 61

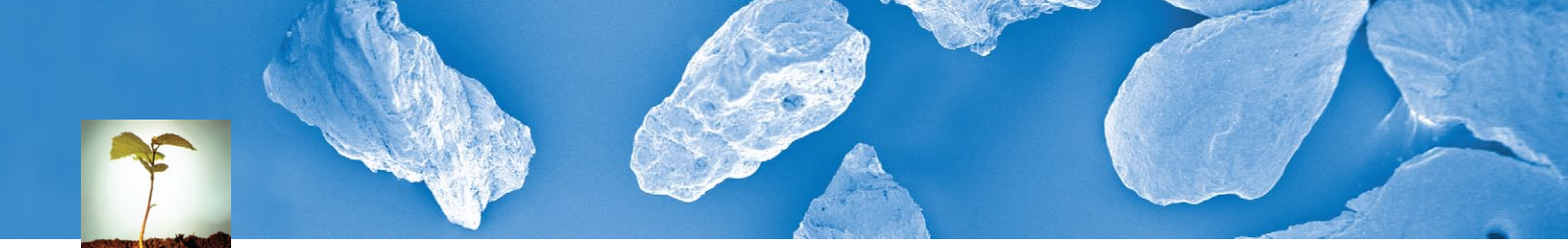

OsteoBiol® by Tecnoss

Combination of bone graft and resorbable membrane for alveolar ridge preservation: a systematic review, meta-analysis, and trial sequential analysis

G Troiano[1]
K Zhurakivska[1]
L Muzio[1]
L Laino[2]
M Cicciù[3]
L Lo Russo[1]

| Department of Clinical and Experimental Medicine, Foggia University, Foggia, Italy
2 | Multidisciplinary Department of Medical- Surgical and Dental Specialties, Second University of Naples, Naples, Italy
3 | Department of Human Pathology, School of Dentistry, University of Messina, Messina, Italy

ORIGINAL ARTICLE
J Periodontol. 2018;89:46–57

ABSTRACT

It is well known that, after tooth extraction, the alveolar ridge undergoes remodelling and resorption, with the undesired result of a reduction of the height and width of the residual ridge. Consequently, alveolar ridge preservation (ARP) techniques are advocated in order to counteract these events and a variety of grafting materials has been tested in the postextractive socket. The aim of this systematic review was to analyze evidence regarding potential benefits of ARP procedures performed with allogenic/xenogenic grafts in combination with a resorbable membrane coverage in comparison with spontaneous healing. Consequently, in this paper seven studies comparing the use of a bone substitute combined with a resorbable membrane in the test group and spontaneous healing of the extraction socket in the control group were included. Materials used in the included studies were the following: six studies reported use of xenogenic grafting materials consisting of cortico-cancellous porcine bone, collagenated cortico-cancellous porcine bone, and bovine bone mineral associated with a collagen membrane, whereas one study reported the use of FDBA combined with a collagen membrane. In all studies, the control group was characterized by spontaneous healing. Horizontal ridge width reduction (HRWR) and vertical ridge height reduction (VRHR) were investigated as primary outcomes and volume changes (VC) as a secondary outcome. Meta-analysis revealed that the combination therapy resulted in a lower rate of resorption for both HRWR (−2.19 mm, 95% confidence interval [CI]: −2.67 to −1.71 mm) and VRHR (−1.72 mm, 95% CI: −2.14 to −1.30 mm).

CONCLUSIONS

According to the results of the meta-analysis, the evidence currently available in the literature is strong enough to conclude that filling postextraction sockets with a bone substitute covered by a resorbable membrane results in a lower rate of resorption, both in vertical and horizontal dimensions, compared with spontaneous healing. The Authors concluded that *"further studies should be directed to compare use of different bone substitutes and membranes and investigate potential and significant variability related to them, as well as to flap design"*.

Grafted with

BONE SUBSTITUTES
OsteoBiol® *Gen-Os®*
OsteoBiol® *mp3®*
OsteoBiol® *Apatos*

MEMBRANE
OsteoBiol® *Evolution*
OsteoBiol® *Lamina*