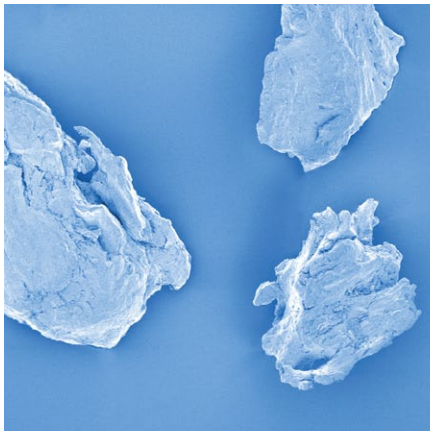
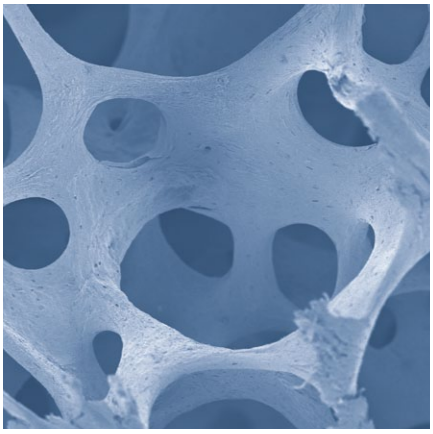
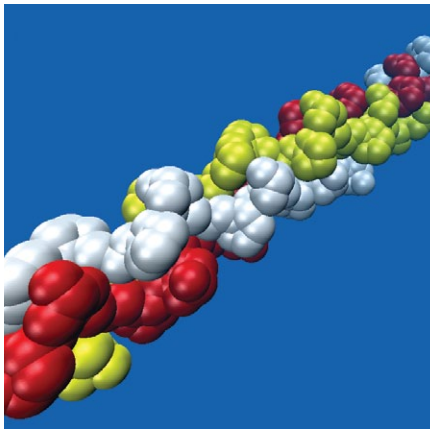
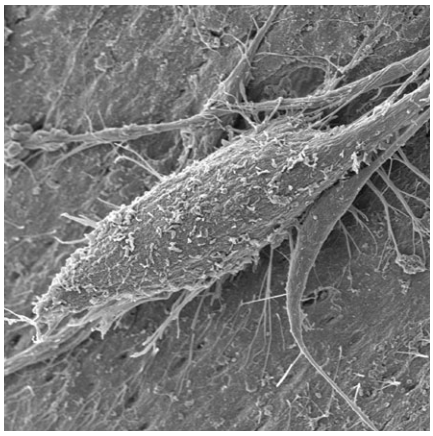
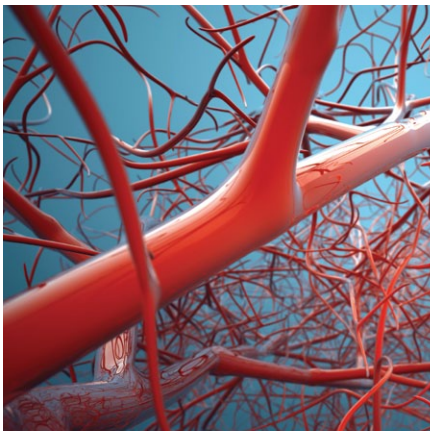
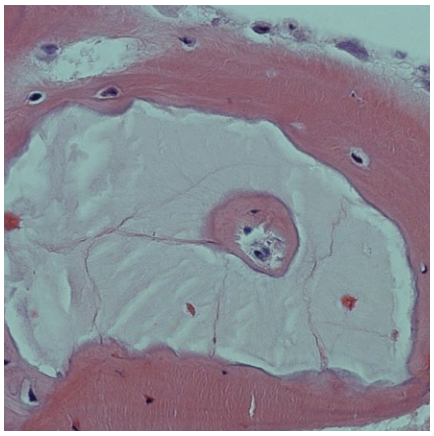

SCIENTIFIC ABSTRACTS

INTERNATIONAL PUBLICATIONS ON OSTEOBIOL® BIOMATERIALS

OsteoBiol®
by Tecnoss

REGENERATION SCIENCE

INSPIRED BY NATURE

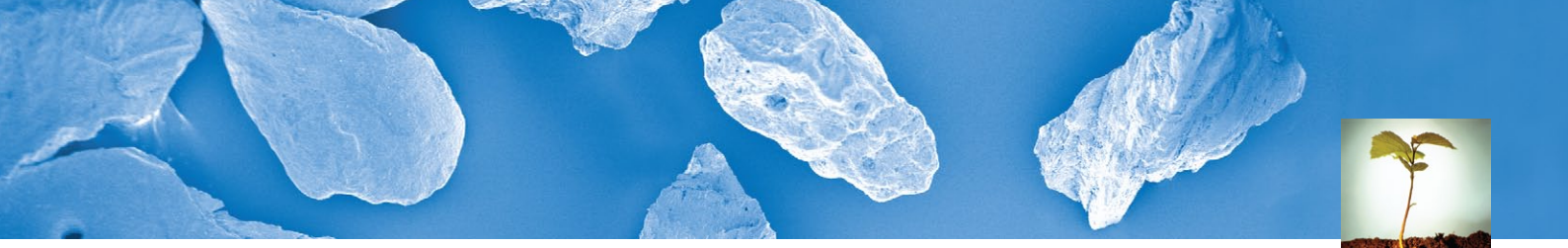

Alveolar regeneration

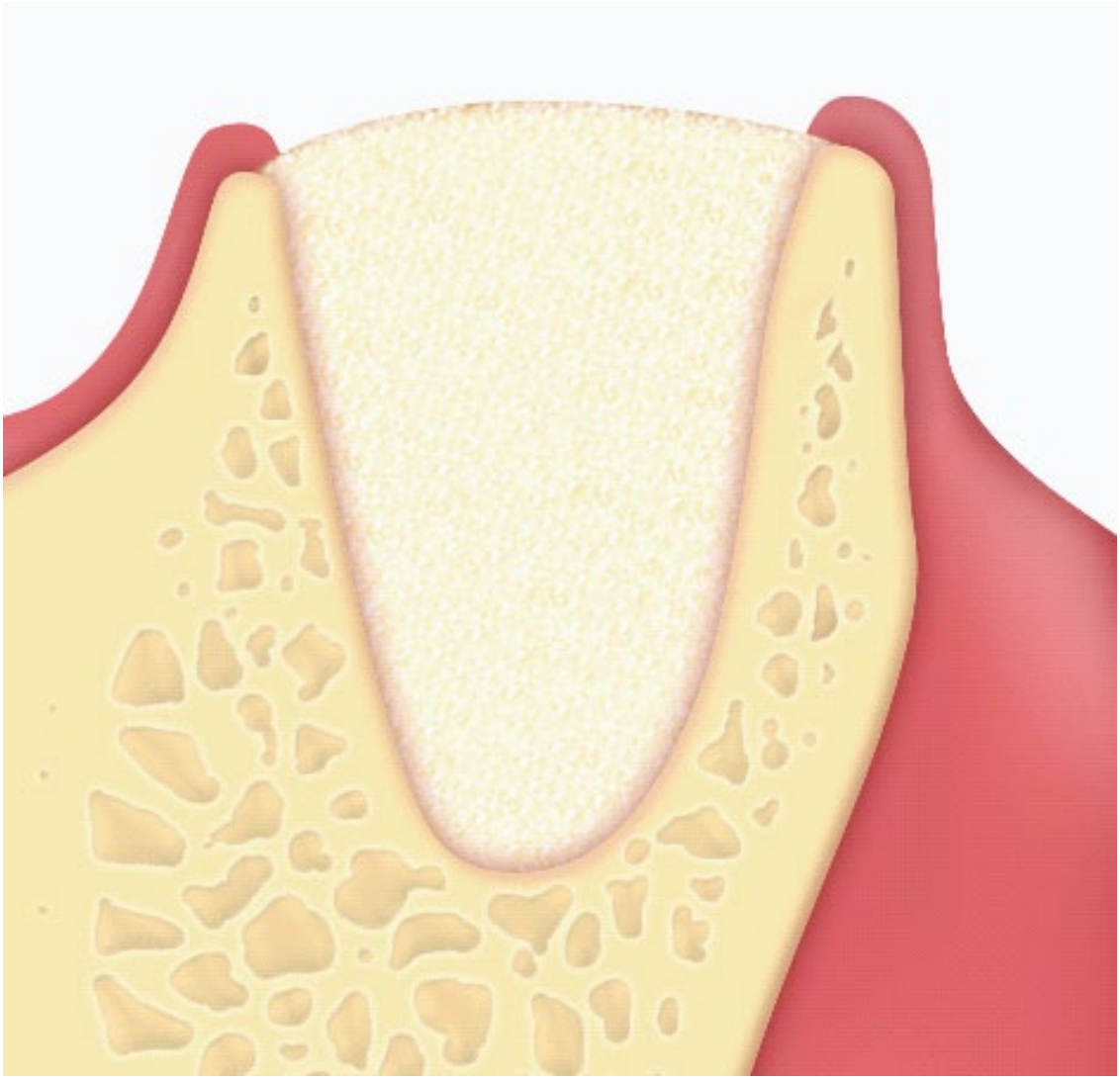

OsteoBiol®
by Tecnoss

REGENERATION SCIENCE

INSPIRED BY NATURE

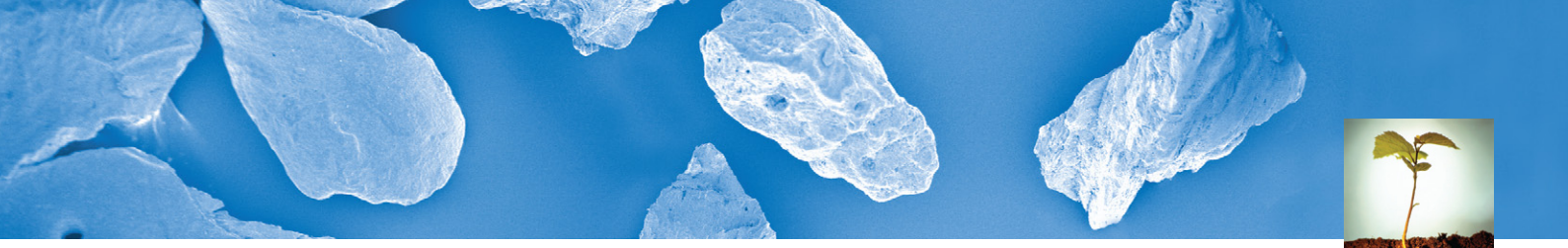

OsteoBiol® by Tecnoss

Single post-extractive ultra-wide 7 mm-diameter implants versus implants placed in molar healed sites after socket preservation for molar replacement: 6-month post-loading results from a randomised controlled trial

M Tallarico[1,2,3]
E Xhanari[4]
M Pisano[5]
G De Riu[1]
A Tullio[6]
S M Meloni[1,5]

1 | University of Sassari, Sassari, Italy
2 | Osstem AIC, Italy
3 | Private Practice, Rome, Italy
4 | Private Practice, Tirana, Albania
5 | DDS, Private Practice, Arzachena, Italy
6 | University of Perugia, Perugia, Italy

ORIGINAL ARTICLE
European Journal of Oral Implantology
2016;9(3):263-275

ABSTRACT

Immediate placement of implants into fresh extraction sockets is an option for replacing missing teeth, with the advantage of reducing the number of surgical interventions required for treatment and the time interval between dental extraction and the placement of implant-supported prostheses. However, this technique involves numerous challenges related to site-specific anatomic, occlusal and biomechanical factors. The present randomised controlled trial (RCT) was conducted with the aim of understanding which procedure would be preferable after having extracted a hopeless molar in both jaws, between immediate post-extractive ultra-wide 7 mm-diameter implants in combination with socket preservation procedures, and socket preservation procedures alone, with delayed implant placement. The aim was to test the hypothesis that there is no difference in clinical, radiographic and aesthetic outcomes positioning single post-extractive ultra-wide 7 mm-diameter implants or waiting 4 months to place the same diameter implant, after molar extraction and socket preservation procedure. Patients requiring one implant-supported single restoration to replace a failed tooth in the molar region of both maxilla and mandible were selected and randomised according to a parallel group design into two arms: implant installation in fresh extraction sockets augmented with cortico-cancellous heterologous bone and porcine derma (group A) or delayed implant installation 4 months after tooth extraction and socket preservation using the same materials (group B). After tooth extraction, the residual alveolar socket around the implant was grafted with cortico-cancellous heterologous bone, with a graft particle size between 250 and 1000 μm (OsteoBiol® *Gen-Os*®, Tecnoss®, Giaveno, Italy). Then, the bone graft was covered with a porcine derma (OsteoBiol® *Derma*, Tecnoss®), shaped according to the shape and dimension of the alveolar socket and stabilised with suture. Outcome measures were implant success and survival; complications; horizontal dimensional changes measured on cone beam computed tomography (CBCT) scans; peri-implant marginal bone level (MBL) changes; implant stability quotient (ISQ); and pink esthetic score (PES).

CONCLUSIONS

The results of this study revealed statistically significant differences both in MBL and horizontal marginal bone level changes between the two investigated approaches, with lower values for socket preservation procedure alone, with delayed implant placement. Both procedures achieved successful results, however, waiting 4 months after tooth extraction and socket preservation procedure was associated with less marginal bone loss. A possible explanation was that a wider diameter implant reduces the positive effect of the socket preservation.

Grafted with

BONE SUBSTITUTE
OsteoBiol® *Gen-Os*®

MEMBRANE
OsteoBiol® *Derma*