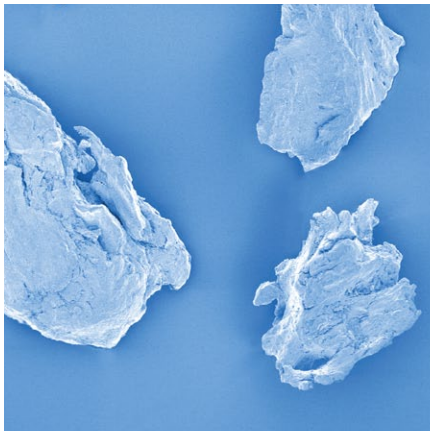
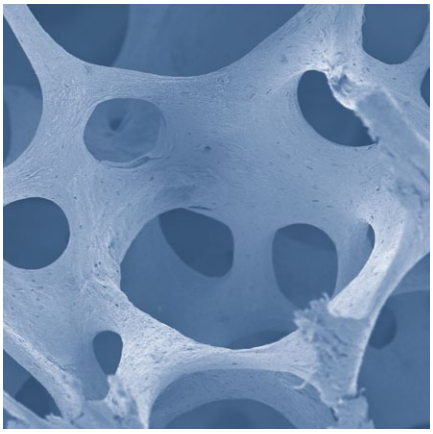
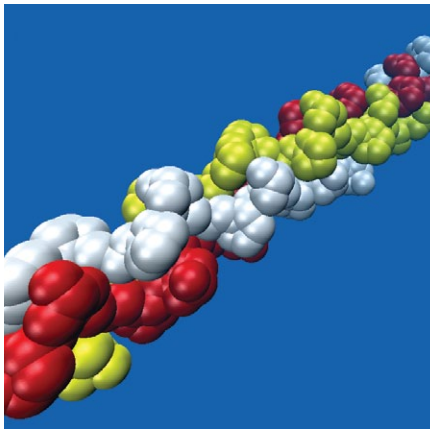
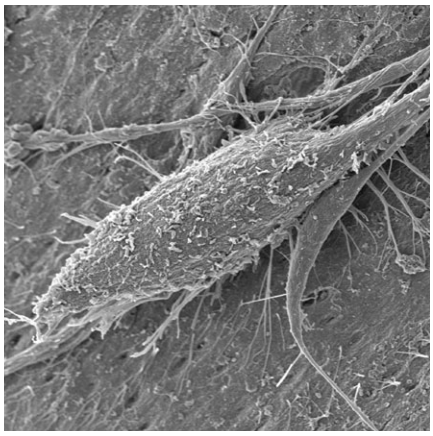
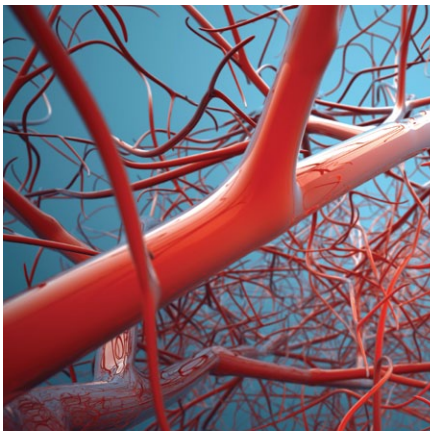
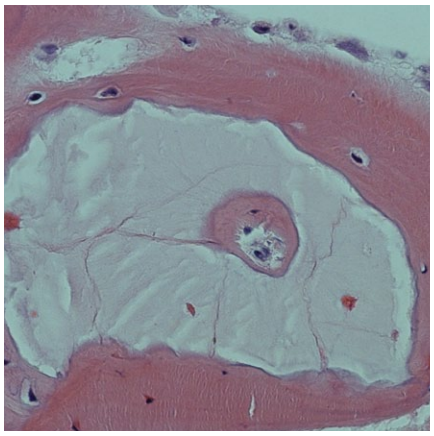

SCIENTIFIC ABSTRACTS

INTERNATIONAL PUBLICATIONS ON OSTEOBIOL® BIOMATERIALS

OsteoBiol®
by Tecnoss

REGENERATION SCIENCE

INSPIRED BY NATURE

Dehiscences and fenestrations

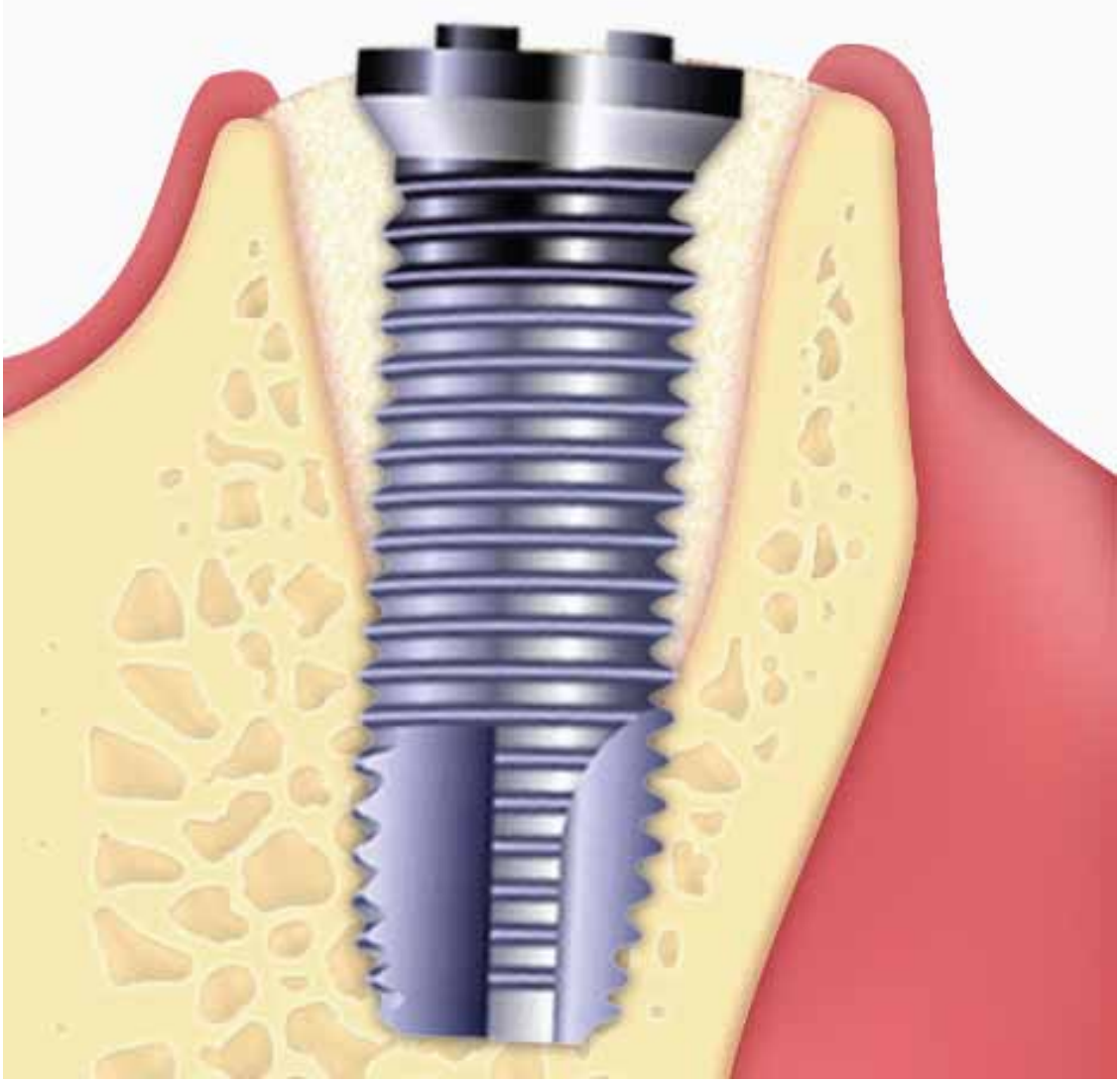

OsteoBiol®
by Tecnoss

REGENERATION SCIENCE

INSPIRED BY NATURE

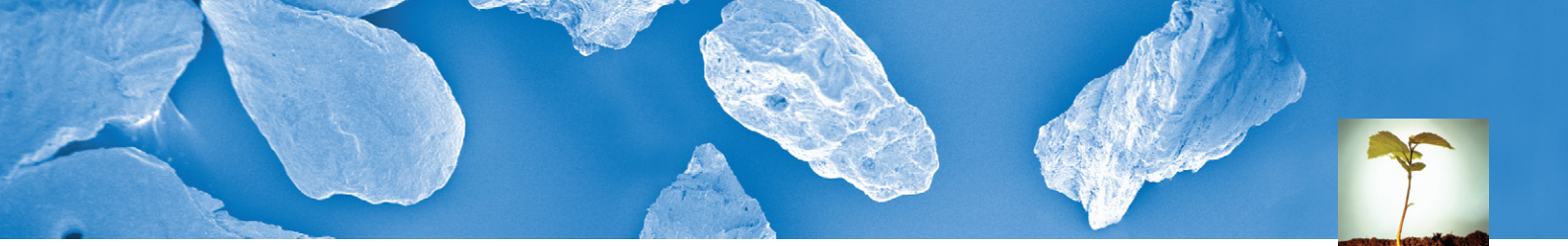

OsteoBiol® by Tecnoss

Buccal bone augmentation around immediate implants with and without flap elevation: a modified approach

U Covani[1]
R Cornelini[2]
A Barone[2]

1 | Department of Biophysical, Medical and Dental Sciences and Technologies, School of Dentistry, University of Genova, Italy
2 | Department of Biophysical, Medical and Dental Sciences and Technologies, Medical School, University of Genova, Italy

ABSTRACT

In literature, there is evidence of the fact that implants placed in fresh extraction sockets reduce not only morbidity rates in patients, but also the total time between tooth removal and the final prosthetic restoration. The aim of this study was to compare the clinical success and bone healing of implants placed in fresh extraction sockets using a flapless procedure compared to those placed with flap elevation. 20 patients (8 male and 12 female) aged 30 to 67 years were included in the study. All the patients selected for this study required the extraction of a natural tooth and were scheduled for immediate implant replacement.

10 implants were placed with flap elevation (control group), and 10 implants were placed without flap elevation (test group). All the sites selected showed a complete bone defect at the facial wall, which required bone augmentation. Bone augmentation was performed with a mixture of collagen gel and cortico-cancellous porcine bone (OsteoBiol® *Gel 40*, Tecnoss®, Giaveno, Italy). The surgical sites were protected at the level of gingival wound with a collagen membrane (OsteoBiol® *Evolution*, Tecnoss®). All grafting procedures were successfully carried out as planned without any complications. All the implants included in this study were 2-stage implants placed at the level of palatal/lingual bone in augmented bone. 6 months after placement, both control and test implants underwent a second-stage surgery and a clinical examination to determine the implant stability quotient (ISQ), the distance between the implant shoulder and the first bone-implant contact (DIB) and the distance between implant shoulder and the crestal bone at the midbuccal aspect (DIC). One implant failed in the test group. Only one implant (test group) showed bone growth over the implant neck at the re-entry procedure. ISQ and DIB did not show any significant differences between the control and test group; however, a higher DIC was found in the test sites compared to the control sites.

CONCLUSIONS

The present study showed that implants placed immediately after tooth extraction in presence of vertical bone defects can be successfully treated either with or without flap elevation, even in the presence of bone defects requiring augmentation procedures. It was also noted that the bone regenerated reached a higher coronal level in the group with flap elevation than in the group without flap elevation. These findings suggest more favorable outcomes in terms of regenerated bone for the flap elevation group.

ORIGINAL ARTICLE
The International Journal of Oral & Maxillofacial Implants
2008 Sept-Oct ;23(5): 841-6

Grafted with

BONE SUBSTITUTE
OsteoBiol® *Gel 40*

MEMBRANE
OsteoBiol® *Evolution*