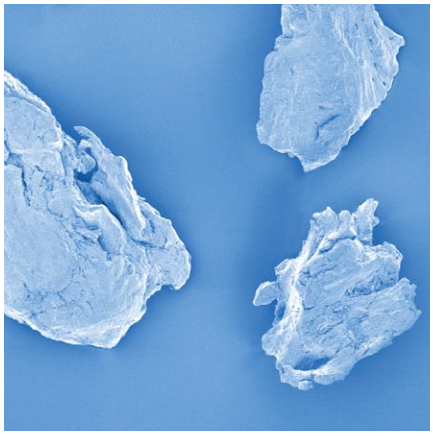
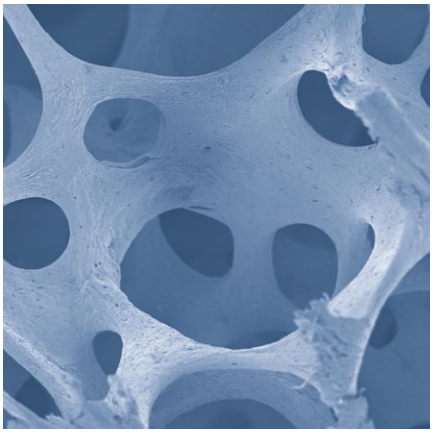
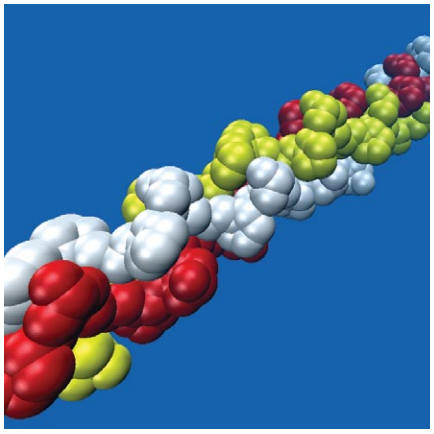
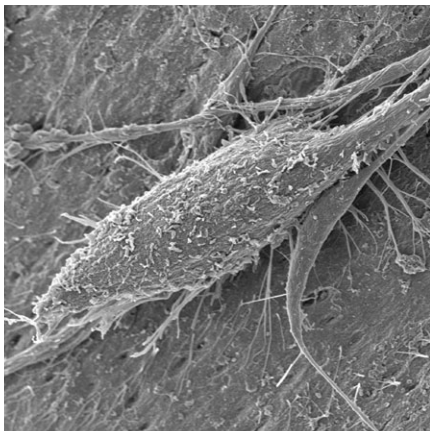
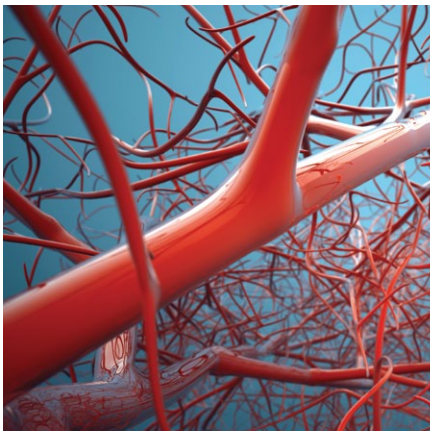
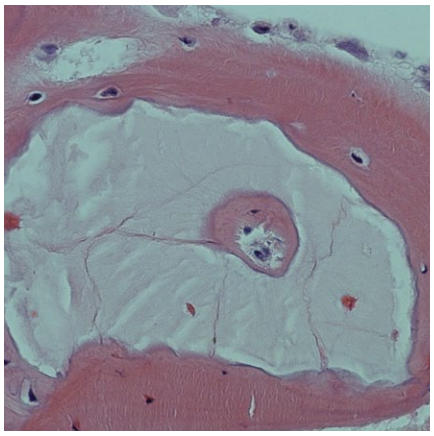

SCIENTIFIC ABSTRACTS

INTERNATIONAL PUBLICATIONS ON OSTEOBIOL® BIOMATERIALS

OsteoBiol®
by Tecnoss

REGENERATION SCIENCE

INSPIRED BY NATURE

Lateral access sinus lift

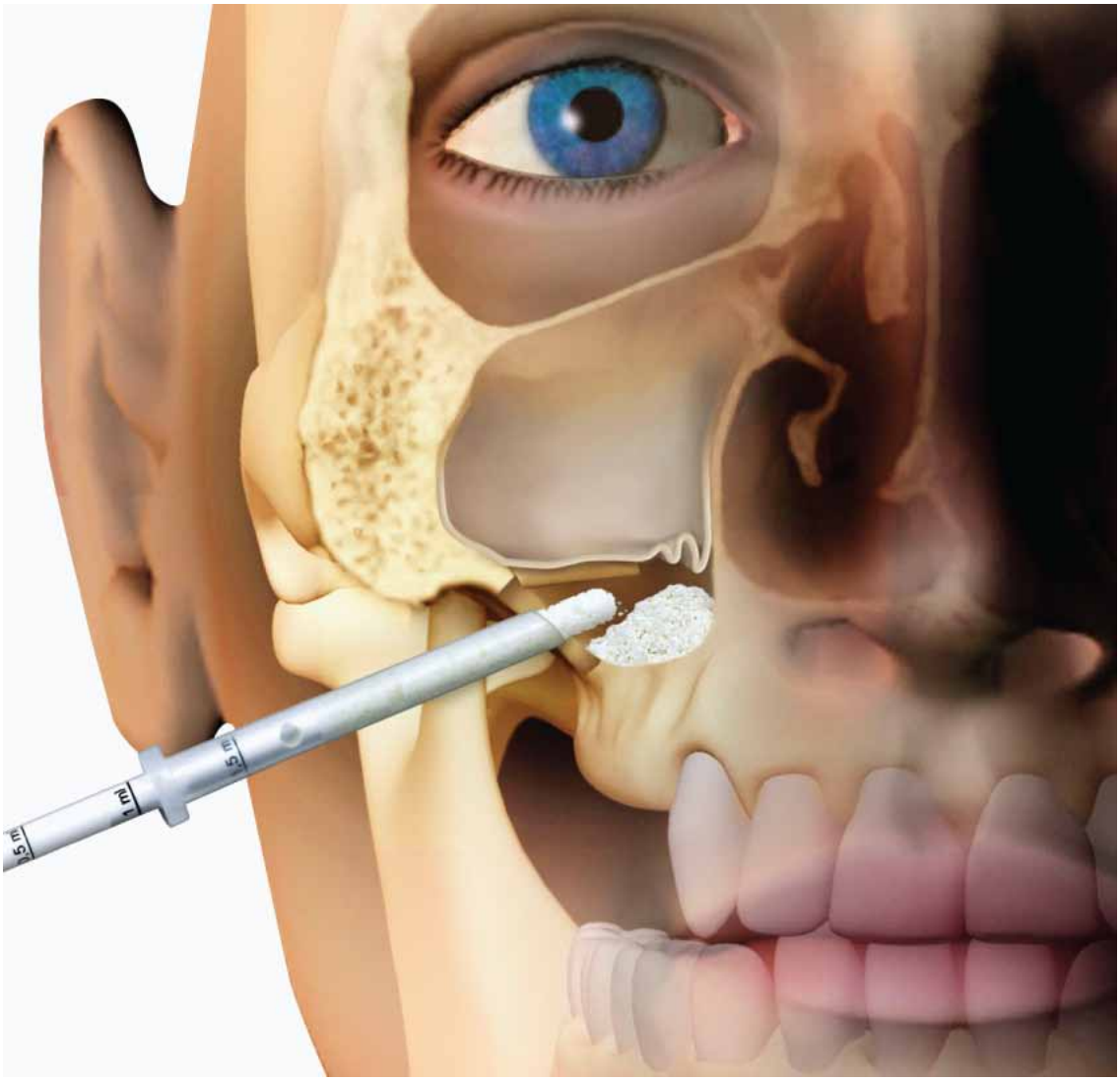

OsteoBiol®
by Tecnoss

REGENERATION SCIENCE

INSPIRED BY NATURE

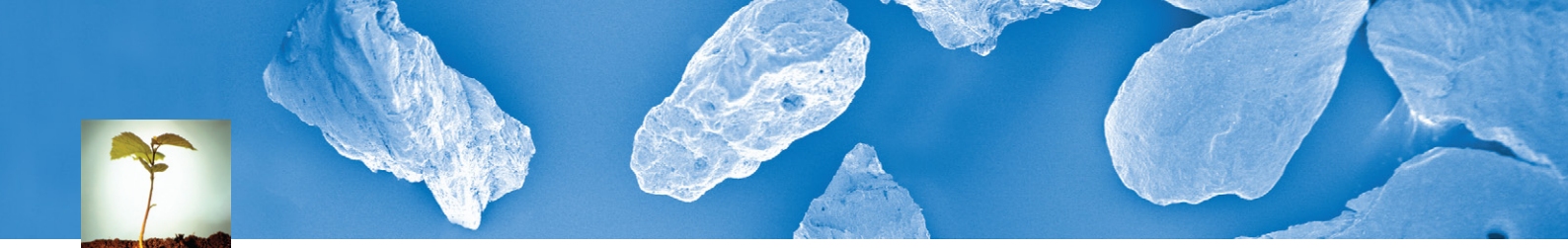

OsteoBiol® by Tecnoss

LATERAL ACCESS SINUS LIFT

004

Maxillary sinus augmentation: histologic and histomorphometric analysis

A Barone[1]
R Crespi[1]
N Nicoli Aldini[2]
M Fini[2]
R Giardino[2]
U Covani[1]

1 | Department of Biophysical, Medical and Dental Sciences and Technologies, Nanoword Institute, School of Dental Medicine, University of Genova, Italy
2 | Experimental Surgery Department, Research Institute, Codivilla Putti-Rizzoli Orthopaedic Institute and Surgical Pathophysiology, Medical School, University of Bologna, Italy

ORIGINAL ARTICLE
The International Journal of Oral & Maxillofacial Implants
2005; Jul-Aug; 20(4):519-25

ABSTRACT

A limited quantity of bone volume, related to an excessive resorption of the alveolar bone following a tooth extraction and enlargement of the maxillary sinus, can complicate the implant placement in the posterior maxilla. In order to allow a predictable implant placement, sinus floor lifting and grafting have been proposed. In this study, the Authors aimed to compare from a histological point of view the use of 100% autogenous bone versus a combination of autogenous bone and cortico-cancellous porcine bone for the sinus floor augmentation procedure.

For this study, 18 patients were selected following these criteria: need for bilateral sinus lifting and grafting, presence of severe maxillary bone atrophy, presence of a residual maxillary sinus floor of less than 3 mm and presence of healthy systemic conditions. The surgery was performed under general anesthesia and the bone for grafting was harvested from the iliac crest.

Each patient received 100% autogenous bone in one randomly selected sinus (control side) and a 1:1 mixture of autogenous bone and cortico-cancellous porcine bone particles (OsteoBiol® *Gen-Os*®, Tecnoss®, Giaveno, Italy) in the controlateral sinus (test side). The bony sinus windows were covered by a resorbable collagen membrane (OsteoBiol® *Evolution*, Tecnoss®). 5 months after surgery, all patients received at least 2 implants on each side of the maxilla and bone biopsy specimens (2 from each side) were taken at the time of implant placement.

The histologic evaluation of the test sites at 5 months showed the presence of some residual cortico-cancellous bone particles and that the incompletely resorbed bone graft was well integrated and in complete continuity with the new bone tissue formation. No significant differences in bone percentages were observed in the bone biopsies from test and control sites.

CONCLUSIONS

In the present study, cortico-cancellous pig bone particles at 5 months became partially resorbed and surrounded by new woven bone. On the basis of the findings from this study, the Authors concluded that the cortico-cancellous pig bone particles have the capacity to support bone augmentation and can be successfully used in a 1:1 mixture with autogenous bone harvested from the iliac crest in case of severe maxillary atrophies (class V Cawood).

Grafted with

BONE SUBSTITUTE
OsteoBiol® *Gen-Os*®

MEMBRANE
OsteoBiol® *Evolution*

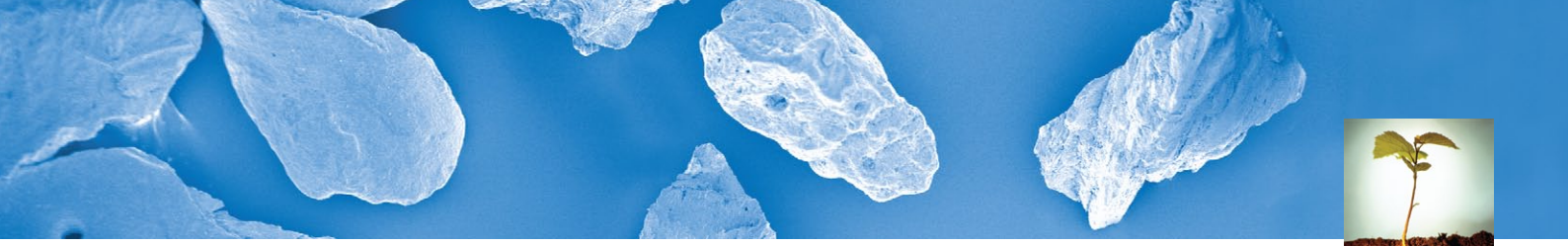

OsteoBiol® by Tecnoss

A clinical study of the outcomes and complications associated with maxillary sinus augmentation

A Barone[1]
S Santini[1]
L Sbordone[2]
R Crespi[1]
U Covani[1]

1 | Department of Biophysical, Medical and Dental Sciences and Technologies, Medical School, University of Genova, Italy
2 | Department of Surgery, University of Pisa, Italy

ABSTRACT

The sinus lift procedure is performed in order to increase the bone volume in the lateral maxilla and allow the use of dental implants. The dental implants can either be placed simultaneously when there is sufficient bone height, or be placed in a second moment, after an augmentation procedure.
The aim of this study was to evaluate the rate of complications in maxillary sinus floor augmentation surgery and the impact of complications on subsequent implant treatment in a patient population with severe maxillary atrophy scheduled for treatment under general anaesthesia.
70 patients (124 sinuses) with severe maxillary atrophy were included in the study for the maxillary sinus augmentation treatment under general anaesthesia. In 93 sinuses, the treatment was performed with autogenous bone alone. The donor sites for bone harvesting included the mandibular symphysis or the antero-upper border of the iliac crest. The remaining 31 sinuses were augmented with a 1:1 mixture of autogenous bone and cortico-cancellous pig bone particles (OsteoBiol® *Gen-Os*, Tecnoss®, Giaveno, Italy). The particles had granulometry between 250 and 1000 μm. The bony sinus windows were covered with a resorbable collagen membrane. Finally, the mucoperiosteal flap was replaced and sutured using vertical interrupted mattress sutures.

CONCLUSIONS

In evaluating the intraoperative complications, the Authors found that the use of an onlay bone graft in conjunction with sinus augmentation appeared to significantly increase the rate of infective complications. Anyway, this study showed no significant correlations between the occurrence of complications and the type of filling material adopted in the maxillary sinus augmentation. Furthermore, it was observed that new bone formation took place within 6 months of the sinus lift operation.
In particular, the Authors concluded that *"no radiographic discrepancies in the amount of bone regenerated were observed between sinuses where only autogenous bone was used and those where a 1:1 mixture of autogenous bone and cortico-cancellous pig bone particles was used"*.

ORIGINAL ARTICLE
The International Journal of Oral & Maxillofacial Implants
2006 Jan-Feb; 21(1):81-5

Grafted with

BONE SUBSTITUTE
OsteoBiol® *Gen-Os*®

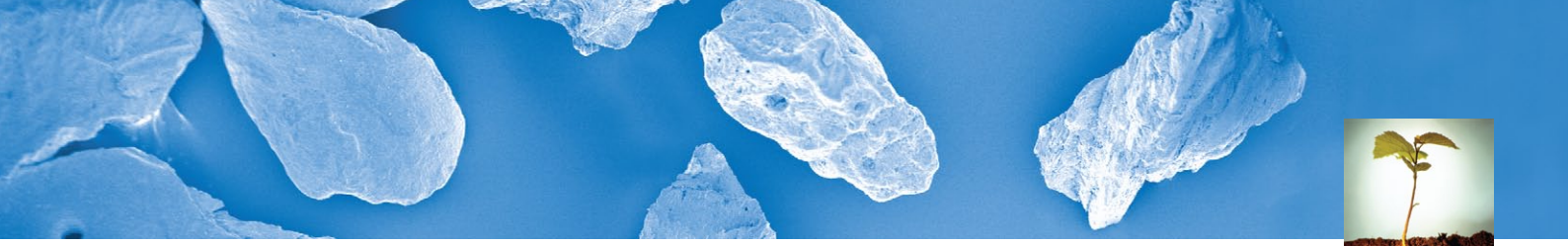

OsteoBiol® by Tecnoss

A collagenated porcine bone substitute for augmentation at Neoss implant sites: a prospective 1-year multicenter case series study with histology

L Pagliani[1,2]
P Andersson[1,3,4]
M Lanza[1,5]
A Nappo[6]
D Verrocchi[1,4,5]
S Volpe[1,7]
L Sennerby[1,3,8]

1 | The Feltre/Fiera Di Primiero Implant Research Group, Feltre, Italy
2 | Private practice, Milano and Legnano, Italy
3 | Private practice, Feltre, Italy
4 | Private practice, Fiera Di Primiero, Italy
5 | Private practice, San Dona Di Piave, Italy
6 | Private practice, Salerno, Italy
7 | Private practice, Rome, Italy
8 | Department of Biomaterials, Institute Clinical Sciences, Sahlgrenska Academy, University of Gothenburg, Sweden

ABSTRACT

It is well known that the presence of localized defects and/or small amounts of bone below the maxillary sinus can compromise implant placement. In such situation, in order to achieve predictable results, it is necessary to perform specific bone augmentation techniques. Different bone substitutes and barrier membranes are commonly used for the augmentation of localized defects and of the maxillary sinus floor and the aim of this study was to evaluate from a clinical and histological point of view a porcine bone (PB) substitute used for augmentation of the alveolar crest or the maxillary sinus floor prior to or in conjunction with implant placement. The biomaterials used were two types of collagenated bone of porcine origin (OsteoBiol® *Gen-Os*® or OsteoBiol® *mp3*®, Tecnoss®, Giaveno, Italy), two types of collagen gel (OsteoBiol® *Gel 40* or OsteoBiol® *Gel 0*, Tecnoss®), and two types of membranes (OsteoBiol® *Evolution Fine* or OsteoBiol® *Lamina Soft X-fine*, Tecnoss®). 19 patients were treated, with a total of 34 implants (Neoss Ltd., Harrogate, UK) placed. Implants were followed with implant stability measurements at placement and abutment connection, and with intraoral radiographs at abutment connection and after at least 1 year of loading. A biopsy for histology and morphometry was taken at the first re-entry operation. The results show that all but one procedure resulted in successful augmentation, with an overall procedure success rate of 94,7% and 90% for maxillary sinus floor augmentations. The histological examination showed the formation of new bone at the PB surface, forming bridges between particles and between particles and preexisting bone. The presence of scalloped resorption lacunae and new osteons inside the particles indicated ongoing resorption/remodeling of the particles.

CONCLUSIONS

The clinical cases presented in this study showed that collagenated PB could effectively be used for bone augmentation of various defects in all the 19 patients. The study included different defects and treatment strategies because the Authors decide to evaluate the use of the PB in consecutive patients with different needs as usually dealt with in everyday practice. This study showed good clinical results when using a PB substitute and barrier membranes for augmentation of the alveolar crest and maxillary sinus and the histology revealed osteoconductive properties of the material and also indicated osteoclastic resorption.

ORIGINAL ARTICLE
Clinical Implant Dentistry and Related Research
2012 Oct;14(5):746-58

Grafted with

BONE SUBSTITUTES
OsteoBiol® *Gen-Os*®
OsteoBiol® *Gel 40*
OsteoBiol® *mp3*®

MEMBRANE
OsteoBiol® *Evolution*

BARRIER -
BONE SUBSTITUTE
OsteoBiol® *Lamina*

COLLAGEN GEL
OsteoBiol® *Gel 0*

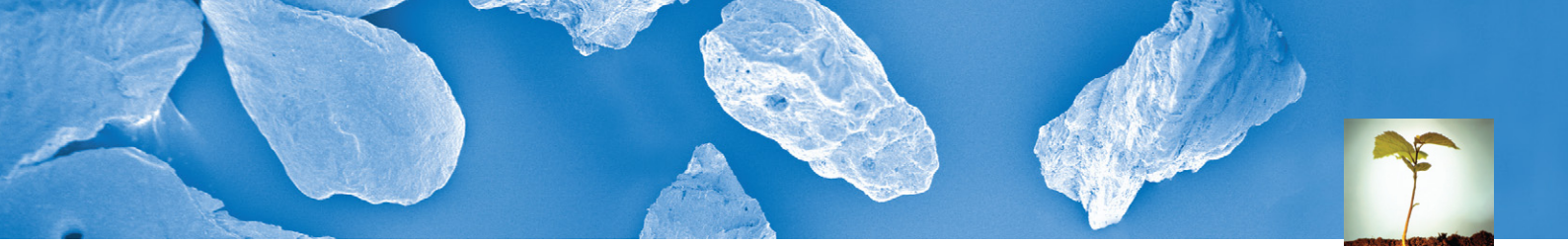

OsteoBiol® by Tecnoss

Use of piezosurgery during maxillary sinus elevation: clinical results of 40 consecutive cases

M Cassetta[1]
L Ricci[2]
G Iezzi[2]
S Calasso[3]
A Piattelli[2]
V Perrotti[2]

1 | Department of Oral and Maxillofacial Sciences, School of Dentistry, University of Rome "La Sapienza", Rome, Italy
2 | Dental School, University of Chieti-Pescara, Chieti, Italy
3 | School of Dentistry, University of Rome "La Sapienza", Rome, Italy

ABSTRACT

Preservation of the sinus membrane is essential for a successful sinus grafting procedure and its integrity is crucial to stabilize grafting materials during the healing period. As perforation occurs most frequently during the rotary osteotomy stage when using a round diamond handpiece, the use of the piezoelectric technique was suggested in order to obtain a greater precision and safety in bone surgery. The aim of this study was to evaluate the performance of piezoelectric devices during sinus elevation to determine the percentage of sinus membrane perforation and the time required to perform the antrostomy and elevation of the membrane. A total of 40 sinuses were included and the elevation procedures were performed by means of a piezosurgery device. The space obtained with the sinus elevation was filled with graft material: either autologous bone or a mixture of 50% autologous bone and 50% deantigenated collagenated bone substitute of porcine origin (OsteoBiol® *Gen-Os*®, Tecnoss®, Giaveno, Italy) was used as a filling material. The total amount of graft material at each site varied according to the extent of maxillary bone resorption and the sinus anatomy. During the sinus elevation procedure, seven perforations occurred, and in those cases, the bony sinus windows were covered with a resorbable membrane (OsteoBiol® *Evolution*, Tecnoss®).

CONCLUSIONS

Postoperative healing was uneventful and free of complications in all patients. After 2 months, at radiographic analysis, an adequate amount of radiopaque material with greater density than the bone was present, and no signs of maxillary sinus infection were observed. Sinus membrane perforation occurred in 7 of 40 cases, representing 17,5% of procedures. These results are similar to those reported by several authors who also found very low perforation percentages using piezoelectric devices. The perforations were repaired using a collagen membrane in direct contact with the sinus membrane.

Based on the results of this study, the Authors affirm that "*sinus augmentation can be successfully performed by means of a piezoelectric device, which was demonstrated to be an attractive alternative to simplify sinus elevation procedures and offer promising results in terms of complications such as sinus membrane perforations*".

ORIGINAL ARTICLE
International Journal of Periodontics & Restorative Dentistry
2012 Dec;32(6):e182-8

Grafted with

BONE SUBSTITUTE
OsteoBiol® *Gen-Os*®

MEMBRANE
OsteoBiol® *Evolution*

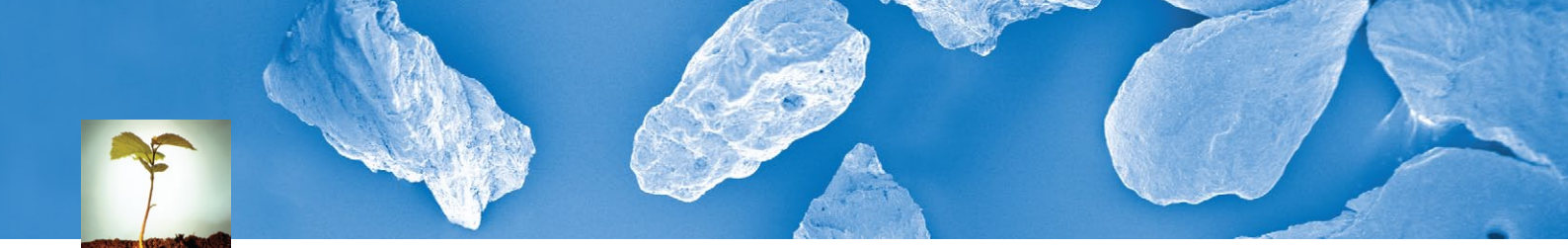

OsteoBiol® by Tecnoss

Bone formation in sinus augmentation procedures using autologous bone, porcine bone, and a 50 : 50 mixture: a human clinical and histological evaluation at 2 months

M Cassetta[1]
V Perrotti[1]
S Calasso[2]
A Piattelli[2]
B Sinjari[2]
G Iezzi[2]

1 | Dental School "Sapienza", University of Rome, Rome, Italy
2 | Department of Medical, Oral and Biotechnological Sciences, University of Chieti-Pescara, Chieti, Italy

ORIGINAL ARTICLE
Clinical Oral Implants Research
2015 Oct;26(10):1180-4

ABSTRACT

In case of a severe resorption following teeth extraction and the pneumatization of the maxillary sinus, it is necessary to adopt maxillary sinus augmentation procedures with biomaterials in order to obtain a sufficient volume of bone tissue to allow a successful implant placement. With reference to bone substitute, the material used must be biologically safe and must satisfy the three fundamental mechanisms of osteogenesis, osteoinduction and osteoconduction.

The purpose of this human study was to compare from the histological, histomorphometrical and clinical point of view the outcomes of autologous bone, porcine bone, and a 50:50 mixture of the two in maxillary sinus augmentation procedures, after a 2-month healing period. In order to do this, 10 patients were included in this study, undergoing two-stage sinus augmentation procedures using 100% autologous bone (Group A), 100% porcine bone (OsteoBiol® *Gen-Os*®, Tecnoss®, Giaveno, Italy - Group B), and a 50:50 mixture of autologous and porcine bone (Group C) were included in this study.

After a 2-month healing period, in group A it was possible to observe trabecular bone with large marrow spaces. Histomorphometry showed that the percentage of newly formed bone was 23.2±3% (median: 23.4), of marrow spaces 60.4±2.3% (median: 60.45) and of residual grafted material 16.4±3.8% (median: 14.9).

In group B, trabecular bone with marrow spaces and residual biomaterial particles was observed.

Histomorphometry showed that the percentage of newly formed bone was 21.6±3.4% (median: 21.6), of marrow spaces 56.1±3.2% (median: 56) and of residual grafted material 22.3±3.5% (median: 22.2).

In group C, trabecular bone with marrow spaces was observed. Histomorphometry showed that the percentage of newly formed bone was 24.5±3.4% (median: 24.5), of marrow spaces 55.1±3.7% (median: 55.1) and of residual grafted material 20.4±3.2% (median: 20.4).

CONCLUSIONS

Based on the results of the study, the Authors concluded that "*the clinical and histological results of this study indicated that porcine bone alone or in combination with autologous bone are biocompatible and osteoconductive materials and can be successfully used in sinus augmentation procedures*".

Grafted with

BONE SUBSTITUTE
OsteoBiol® *Gen-Os*®

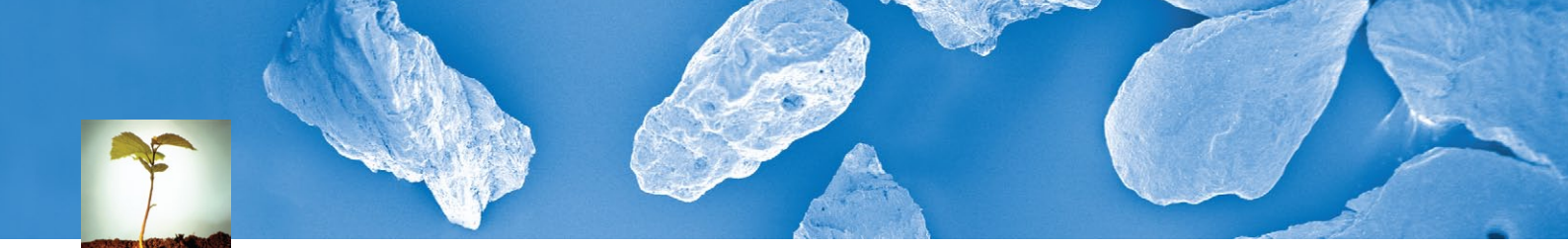

OsteoBiol® by Tecnoss

Histomorphometric outcomes after lateral sinus floor elevation procedure: a systematic review of the literature and meta-analysis

S Corbella[1,2]
S Taschieri[1,2]
R Weinstein[1,2]
M Del Fabbro[1,2]

1 | Department of Biomedical, Surgical and Dental Sciences, Università degli Studi di Milano, Milan, Italy
2 | IRCCS Istituto Ortopedico Galeazzi, Milan, Italy

ORIGINAL ARTICLE
Clinical Oral Implants Research
2016 Sep;27(9):1106-22

ABSTRACT

Very often, the progressive resorption of the alveolar bone caused by tooth loss in the posterior maxilla needs a bone augmentation procedure in order to increase the available bone volume for the placement of dental implants needed to support a fixed prosthetic rehabilitation.
In literature it has been reported that the lateral approach sinus floor elevation (LASFE) can be safely applied in cases of posterior maxilla atrophy, leading to a high implant survival rate.
The aim of the present systematic review of the literature and meta-analysis was to investigate the histomorphometric outcomes of LASFE (Lateral approach sinus floor elevation) surgery in order to evaluate different bone substitute materials (AB, autogenous bone; BB, Bovine bone, AG, allograft; FDBA, freeze-dried bone allograft; HA, hydroxyapatite; PB, porcine bone; PRP, platelet-rich plasma) performances related to new bone formation. After an electronic and manual search, 84 articles were included in the quantitative synthesis and 16 of them in the meta-analysis of comparative studies. Taking into consideration the articles selected, a total of 1846 subjects were treated, and a total of 2224 biopsies were taken and examined. Recorded data were statistically analyzed evaluating percentage of new bone volume, residual biomaterial, and connective/soft tissues in the biopsies. The results show that the use of autogenous bone (AB) alone led to a significantly higher new bone formation if compared with bovine bone (BB) alone ($P = 0.04$), while no significant difference was found when the latter was compared with a mixture of AB and BB ($P = 0.52$). Grafts composed of BB showed significantly greater new bone formation as compared to hydroxyapatite (HA) ($P < 0.001$) while a mixture of tricalcium phosphate (TCP) and HA achieved better outcomes than BB ($P < 0.001$).
PB alone showed at six months a new bone volume range between 31.4% and 43.9%.

CONCLUSIONS

None of the biomaterials used for LASFE procedures demonstrated a significant and predictable superiority regarding new bone formation. The observation that, in comparative studies, the amount of new bone volume was higher for AB than for BB could not be confirmed by clinical results and so it seems that when donor site morbidity is a concern, BB and a mixture of TCP and HA could be considered as predictable alternative with promising results. Anyway, the Authors concluded that *"more randomized, controlled clinical trials providing individual data about the characteristics of the analyzed specimen (size and site of biopsy) and of the residual bone height before intervention may help to achieving a deeper knowledge of the histologic behavior of biomaterials in LASFE procedures"*.

Grafted with

BONE SUBSTITUTE
OsteoBiol® *Apatos*
OsteoBiol® *mp3®*
OsteoBiol® *Gen-Os®*

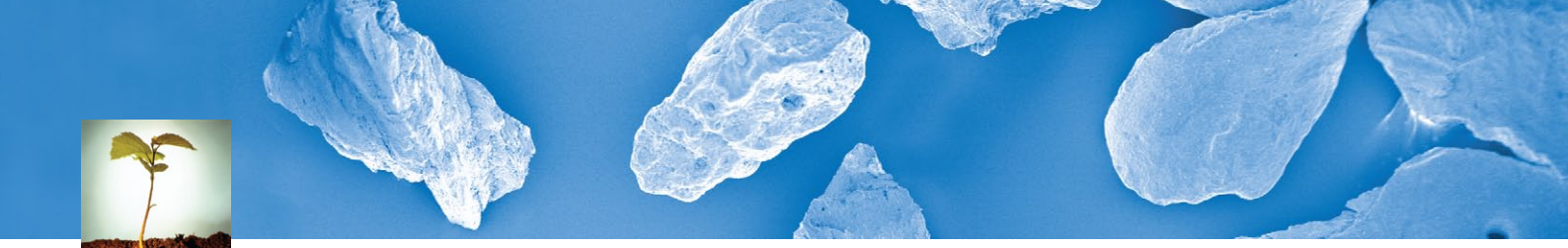

OsteoBiol® by Tecnoss

Molecular, cellular and pharmaceutical aspects of bone grafting materials and membranes during maxillary sinus-lift procedures. Part 2: detailed characteristics of the materials

G Iezzi[1]
A Piattelli[1]
A Giuliani[2]
C Mangano[3]
A Barone[4]
L Manzon[5]
M Degidi[6]
A Scarano[7]
A Filippone[8]
V Perrotti[1]

1 | Department of Medical, Oral and Biotechnological Sciences, Dental School, University G. D'Annunzio of Chieti-Pescara, Chieti, Italy
2 | Department of Odontostomatologic and Specialized Clinical Sciences – Section of Biochemistry, Biology and Physics, Polytechnic University of Marche, Ancona, Italy
3 | Private Practice, Gravedona (CO), Italy
4 | Department of Surgical, Medical, Molecular and Critical Area Pathology, University of Pisa, Pisa, Italy; Tuscan Stomatologic Institute, Versilia General Hospital, Lido di Camaiore (LU), Italy
5 | Sapienza University of Rome, Rome, Italy
6 | Private Practice, Bologna, Italy
7 | Center for Research on Ageing and Translational Medicine, CeSI-MeT, University of Chieti-Pescara, Chieti, Italy
8 | Department of Neurosciences and Imaging, Section of Radiological Sciences, University G. D'Annunzio of Chieti-Pescara, Chieti, Italy

ORIGINAL ARTICLE
Current Pharmaceutical Biotechnology
2017, 18, 33-44

ABSTRACT

Bone substitute materials (BSBs) can be classified into four groups according to their origin: autogenic (bone originating from the same patient), allogenic (bone originating from another person), xenogenic (bone originating from another species) and synthetic (with no biological origin). Their use in bone tissue regeneration has been widely validated and various grafts or combination of bone substitute materials have been used in sinus lift procedures. Knowing the properties of each graft enables individual treatment concepts as the choice of the best BSB is crucial for success in maxillary sinus augmentation procedures. In this article, the aim of the Authors is to provide an overview of most of the materials currently available for sinus lift, with a specific focus on their histological, molecular, cellular and pharmaceutical aspects.
In their overview, the Authors examined collagenated BSB of porcine origin too (OsteoBiol®, Tecnoss®, Giaveno, Italy). In the literature review, porcine bone has been reported to have a microstructure similar to human bone. Most of the grafted porcine bone particles were surrounded by newly formed bone with large osteocyte lacunae and the newly formed bone was always in tight contact to the grafted particles, and no gaps were evident at the bone-particles interface. No inflammatory cells and multinucleated giant cells were detected around the particles or at the interface with bone. No osteoclasts were evident around the graft particles. Moreover, porcine bone has been demonstrated to be osteoconductive, with no adverse reactions, no inflammatory infiltrate and this material has been described as a resorbable graft material, with clear active resorption signs of its particles.

CONCLUSIONS

Following a detailed description of the different BSBs, the Authors concluded that: *"the results of the present overview showed that all these BSBs can be used with success in maxillary sinus augmentation procedures presenting good biocompatibility and osteoconductive properties, with osteoblastic cells forming bone directly in contact with the material surface and without histological signs of adverse reactions. Most of these biomaterials seem to be gradually resorbed, and partially replaced by newly formed bone."*

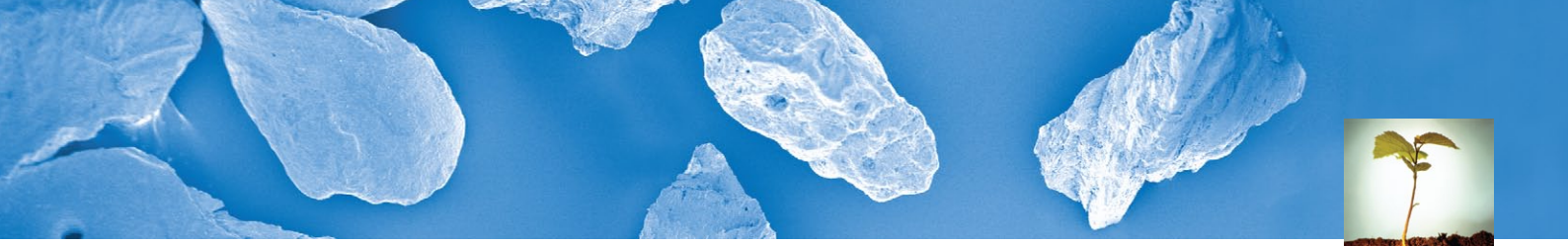

OsteoBiol® by Tecnoss

Short (6-mm) dental implants versus sinus floor elevation and placement of longer (≥10-mm) dental implants: randomized controlled trial with a 3-year follow-up

S Bechara[1]
R Kubilius[1]
G Veronesi[2]
JT Pires[3]
JA Shibli[3]
FG Mangano[4]

1 | Department of Oral and Maxillofacial Surgery, Lithuanian University of Health Science, Kaunas, Lithuania
2 | Department of Clinical and Experimental Medicine, University of Varese, Varese, Italy
3 | Department of Periodontology and Oral Implantology, Dental Research Division, Guarulhos University, Guarulhos, Sao Paulo, Brazil
4 | Department of Surgical and Morphological Sciences, Dental School, University of Varese, Varese, Italy

ORIGINAL ARTICLE
Clinical Oral Implants Research
2017;28;1097-1107

ABSTRACT

Edentulous posterior maxilla is often characterized by reduced bone volume, especially due to severe post-extraction alveolar crest resorption, and this anatomic limitation can jeopardize osseointegration and therefore the possibility to have a functional and aesthetic implant-supported restoration. In order to obtain a sufficient bone height for implant insertion, a reconstructive bone surgery is often needed and maxillary sinus floor elevation has become the more reliable and commonly used procedure. As the use of short implant (6-mm) can be an alternative to sinus floor elevation, the aim of this 3-year follow-up randomized clinical trial was to investigate this alternative to sinus floor elevation (SFE) and placement of longer (≥10-mm) implants in the posterior maxilla. Thirty-three patients were included in the study and randomly assigned either to receive one to four short (6-mm) implants (test group) or to undergo augmentation procedures and simultaneous placement of one to four standard-length (≥10-mm) implants (control group). In both groups, tapered implants (AnyRidge, MegaGen, Gyeongbuk, South Korea) were placed. In the control group, the augmentation procedures consisted in the insertion of collagenated porcine particulate bone graft (OsteoBiol® *Gen-Os*®, Tecnoss®, Giaveno, Italy) in a lateral window below the lifted membrane, with simultaneous implant placement. The primary outcomes of the study were implant survival, stability, marginal bone loss, and complications associated with the two treatment options; secondary outcomes included treatment time and cost and patient satisfaction. At 3 years, implant survival rates were 100% and 95.0% for test group and control group, respectively, with a difference that was not statistically significant. The mean ISQ values of both groups did not differ at placement (68.2 vs. 67.8, P = 0.1), at delivery of the final restoration (69.5 vs. 69.4, P = 0.9), and after 1 year (71.0 vs. 71.5, P = 0.1). At the 3 years follow-up, the mean ISQ in the control group was significantly higher than that of the test group (72.4 vs. 71.6, P = 0.004). Mean MBL was significantly higher in the control group both at 1 year (0.14 mm vs. 0.21 mm, P = 0.006) and at 3 years (0.20 mm vs. 0.27 mm, P = 0.01). Surgical time and cost were significantly higher in the control group than in the test one and patient satisfaction was high in both groups.

CONCLUSIONS

In the present randomized clinical trial, both short (6-mm) implants and long (≥10-mm) implants in combination with sinus floor elevation provided good results up to 3 years after loading; however, with 6-mm short implants, the treatment was faster and less expensive. Anyway, in order to confirm these results, long-term randomized controlled trials on larger samples of patients are needed.

Grafted with

BONE SUBSTITUTES
OsteoBiol® *Gen-Os*®

MEMBRANE
OsteoBiol® *Evolution*

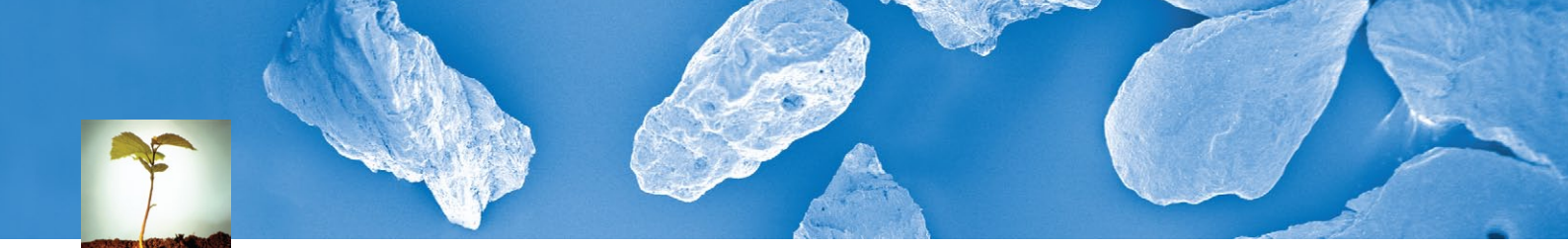

OsteoBiol® by Tecnoss

Management of acute maxillary sinusitis after sinus bone grafting procedures with simultaneous dental implants placement – a retrospective study

L Chirilă[1,2]
C Rotaru[3,5]
I Filipov[4,5]
M Săndulescu[3,6]

1 | Dan Theodorescu Clinical Hospital of Oral and Maxillo-Facial Surgery, Bucharest, Romania
2 | Department of Oral and Maxillo-Facial Surgery, Faculty of Dental Medicine, Carol Davila University of Medicine and Pharmacy, Bucharest, Romania
3 | Dental Concept Studio, Bucharest, Romania
4 | Opera Dental, Bucharest, Romania
5 | MINEC, Bucharest, Romania
6 | Department of Oral Implantology, Faculty of Dental Medicine, Carol Davila University of Medicine and Pharmacy, Bucharest, Romania

ORIGINAL ARTICLE
Bmc Infectious Diseases
2016 Mar 8;16 Suppl 1:94

ABSTRACT

The complications of sinus lift procedure are considered to be low and are represented by acute maxillary sinusitis, wound dehiscence, and Schneiderian membrane perforations with consecutive spilling of the grafting material in the sinus cavity. In this study, the Authors aimed to evaluate the incidence of acute maxillary sinusitis in case of lateral window sinus lift with simultaneous implant insertion. Between 2013 and 2015, 116 patients received 245 dental implants with concomitant bone augmentation of the maxillary sinus floor. The sinus lifting procedure was bilateral in 35 patients and unilateral in 81 patients (a total of 151 sinuses). Depending on the volume that was required to be augmented, the grafting material used was a mix of xenograft (Cerabone®, Botiss biomaterials GmbH, Gerlingen, Germany or OsteoBiol® *Gen-Os*®, Tecnoss®, Giaveno, Italy) and autologous bone chips, human allograft (Maxgraft®, Botiss biomaterials GmbH) with autologous bone chips, a mix of xenograft and allograft or alloplastic grafting material (Maxresorb®, Botiss biomaterials GmbH). Based on the patients' preferences, dental implants used were either MIS (Medical Implant System, MIS Implant Technologies Ltd, Shlomi, Israel) or Megagen (MegaGen, Gyeongsan, Daegu, South Korea), with diameters varying from 3.75 to 5.5 mm and length varying from 10 to 13 mm. Maxillary sinusitis occurred in 5 patients (4.3 %), with headache, locoregional pain, cacosmia, inflammation of the oral buccal mucosa and rhinorrhea or unilateral nasal discharge. To solve the sinusitis, in 3 patients the grafting material was removed, in 1 patient the grafting material was removed together with all the implants, and in 1 patient only 2 implants and the grafting material were removed, leaving 1 implant in place. The sinus cavity was irrigated with metronidazole solution and antibiotic therapy with clindamycin and metronidazole was prescribed for 10 days. Following this treatment, all signs of infection disappeared within 5 to 7 days and normal sinus function and drainage were restored.

CONCLUSIONS

In case of acute sinusitis, this complication has to be managed immediately to avoid further complications like pansinusitis, osteomyelitis of the maxillary bone, or the spreading of the infection in the infratemporal space or orbital cavity. During all the steps of the procedure, it is mandatory to pay attention not to obliterate the ostium, impairing maxillary sinus clearance.

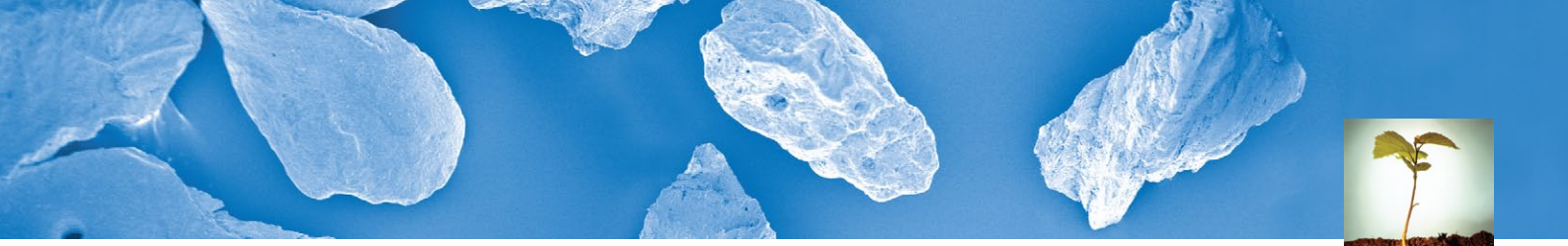

OsteoBiol® by Tecnoss

Influence of the position of the antrostomy in sinus floor elevation assessed with cone-beam computed tomography: a randomized clinical trial

S Kawakami[1]
NP Lang[3,4]
T Iida[1,2]
M Ferri[5,6]
KA Apaza Alccayhuaman[2]
D Botticelli[2]

1 | Department of Oral Implantology, Osaka Dental University, Osaka, Japan
2 | ARDEC Academy, Rimini, Italy
3 | University of Bern, Bern, Switzerland
4 | Center for Dental Medicine, University of Zurich, Zurich, Switzerland
5 | ARDEC Foundation, Cartagena de Indias, Bolívar, Colombia
6 | Rafael Núñez University Corporation, Bolívar, Colombia

ABSTRACT

Augmentation procedures in the distal regions of the edentulous maxilla are necessary in order to allow implant rehabilitation. The aim of the present study was to evaluate dimensional variations of augmented sinus volumes after sinus floor elevation using a lateral approach placing the antrostomy close to the sinus floor or more cranially to it. For the purpose of the study, 24 healthy volunteers, presenting an edentulous atrophic zone in the posterior segment of the maxilla requiring sinus floor elevation and a fixed oral rehabilitation, were recruited. The lateral approach was adopted placing the antrostomy randomly either close to the level of the sinus floor (group A) or approximately 3-4 mm cranially (group B). After the window preparation and the sinus mucosa elevation, the elevated space was filled with a resorbable collagenated cortico-cancellous porcine bone (250–1000 μm; OsteoBiol® *Gen-Os*®, Tecnoss®, Giaveno, Italy). A collagen membrane (0,3 mm; OsteoBiol® *Evolution*, Tecnoss®) was placed to cover the access window, and silk sutures were provided to secure the flaps. Cone-beam computed tomography (CBCT) was done before surgery (T0) and after 1 week (T1) and 9 months (T2) in order to analyse the dimensional variations. At T1, the sinus floor was found to be elevated by 9.8 ± 2.1 mm in group A and 10.9 ± 1.9 mm in group B. At T2, shrinkage of 2.0 ± 1.7 mm in group A and 1.4 ± 2.5 mm in group B was observed. The area was reduced approximately 18-24% between T1 and T2. The sinus mucosa width increased by 4.3-5 mm between T0 and T1, and regained the original dimensions at T2.

CONCLUSIONS

As demonstrated in the present study, following the lateral approach for maxillary sinus floor elevation, the volume of the augmentation seems to be dependent on the location of the access antrostomy. After 9 months, it was evident that the more cranial the antrostomy, the greater the augmentation height.

ORIGINAL ARTICLE
Journal Of Investigative And Clinical Dentistry
2018 Nov;9(4):E12362

Grafted with

BONE SUBSTITUTES
OsteoBiol® *Gen-Os*®

MEMBRANE
OsteoBiol® *Evolution*

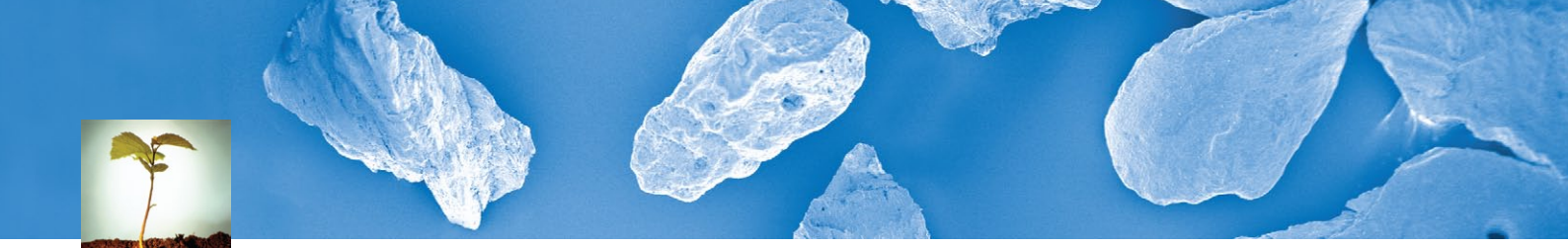

OsteoBiol® by Tecnoss

Sinus membrane elevation with heterologous cortical lamina: a randomized study of a new surgical technique for maxillary sinus floor augmentation without bone graft

A Scarano[1]
P Santos de Oliveira[2]
T Traini[1]
F Lorusso[3]

1 | Department of Medical, Oral and Biotechnological Sciences and CeSi-Met, "G. D'Annunzio" University of Chieti-Pescara, Chieti, Italy
2 | Department of Oral Implantology, Dental Research Division, College Ingà, UNINGÁ, Cachoeiro de Itapemirim, Espirito Santo, Brazil
3 | Department of Medical, Oral and Biotechnological Sciences University of Chieti-Pescara, Chieti, Italy

ORIGINAL ARTICLE
Materials 2018, 11, 1457

ABSTRACT

In case of edentulism in atrophic posterior maxilla, different surgical techniques have been proposed in order to have a sufficient bone volume for implant supported rehabilitation. Together with the surgical techniques, the use of allografts, xenografts and alloplasts has been reported in the literature to help bone formation, thanks to their osteoinductive, osteoconductive and osteogenic properties. The aim of this randomized controlled clinical trial was to compare the efficacy of two different techniques for maxillary sinus augmentation using a lateral window approach: heterologous cortical lamina without any grafting material versus 100% collagenated granular collagenated porcine bone. Twenty-three patients, requiring maxillary sinus augmentation, were divided in two groups. In Group I, the sinus was filled with collagen porcine bone (OsteoBiol® *Gen-Os*®, Tecnoss®, Giaveno, Italy) and a collagen membrane (OsteoBiol® *Evolution*, Tecnoss®) was used to close the lateral window of the sinus. In Group II, the sinus was treated with heterologous cortical lamina only (OsteoBiol® *Lamina*, Tecnoss®) of 1 mm thickness, modelled and positioned in the sinus as a new sinus roof. Radiographically, in Group I bone grafts showed increased hyperdensity between immediate postoperative and after six months healing, with higher density than native bone. In the second surgical phase, the sinus wall was found to be totally healed in all cases. No gaps were present at the bone–porcine bone interface that was always in close contact with the graft particles. In the cortical lamina group, newly formed bone was present histologically, newly formed vessels and new bone trabeculae were seen throughout the large marrow spaces. The histological results showed new bone formation in both groups. There was a statistically significant difference in the surgical time required to complete the augmentation procedures: 18.3 ± 2.1 min for lamina treated sites versus 12.5 ± 3.1 min for porcine bone treated sites.

CONCLUSIONS

This study has reported good results of sinus membrane elevation, with or without bone graft. Even if sinus treated with bone lamina showed a greater volumetric contraction, the overall results led the Authors to conclude that "*the use of heterologous cortical lamina is a valid technique for the mechanical support of sinus membranes resulting in only bone tissue formation and not mixed with the graft. The graft material was biocompatible and not completely resorbed after six months, although the remains were integrated into the bone*".

Grafted with
BONE SUBSTITUTES
OsteoBiol® *Gen-Os*®
MEMBRANE
OsteoBiol® *Evolution*
OsteoBiol® *Lamina*