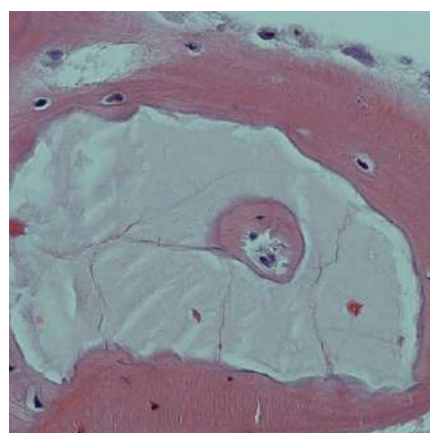
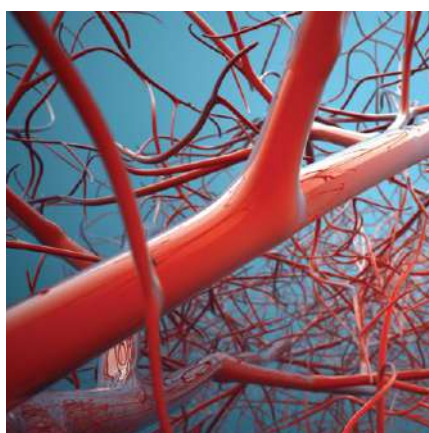
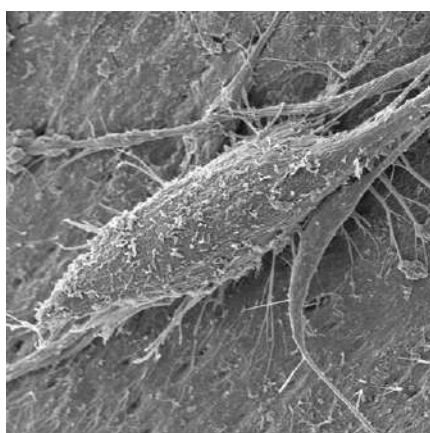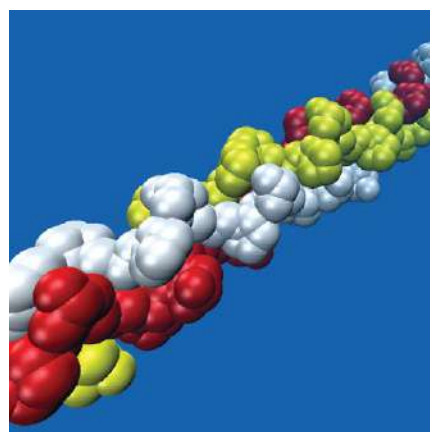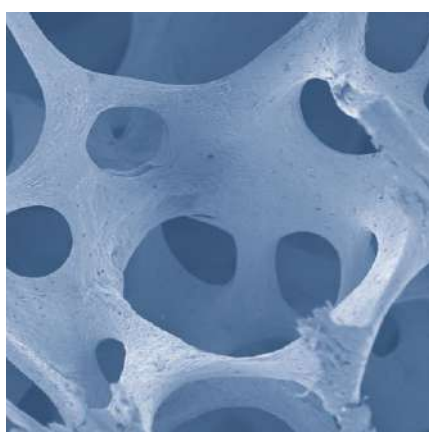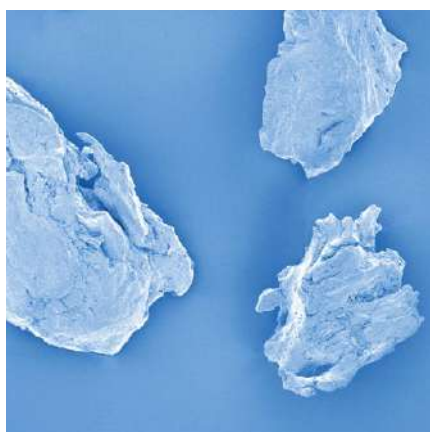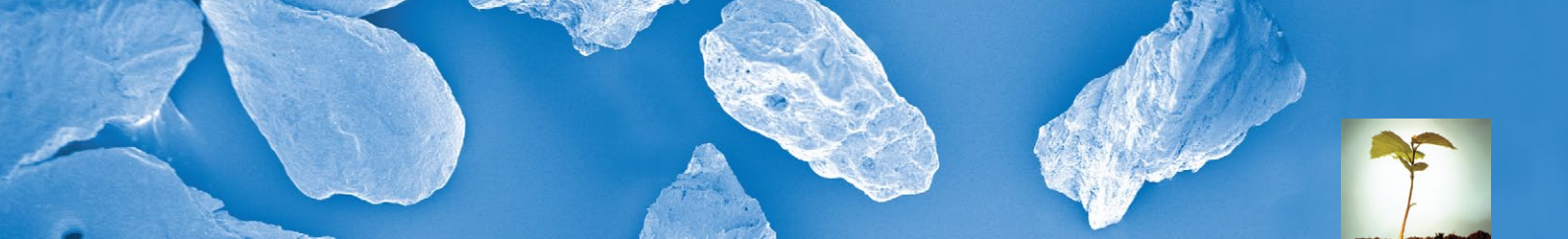
SCIENTIFIC ABSTRACTS

INTERNATIONAL PUBLICATIONS ON OSTEOBIOL® BIOMATERIALS

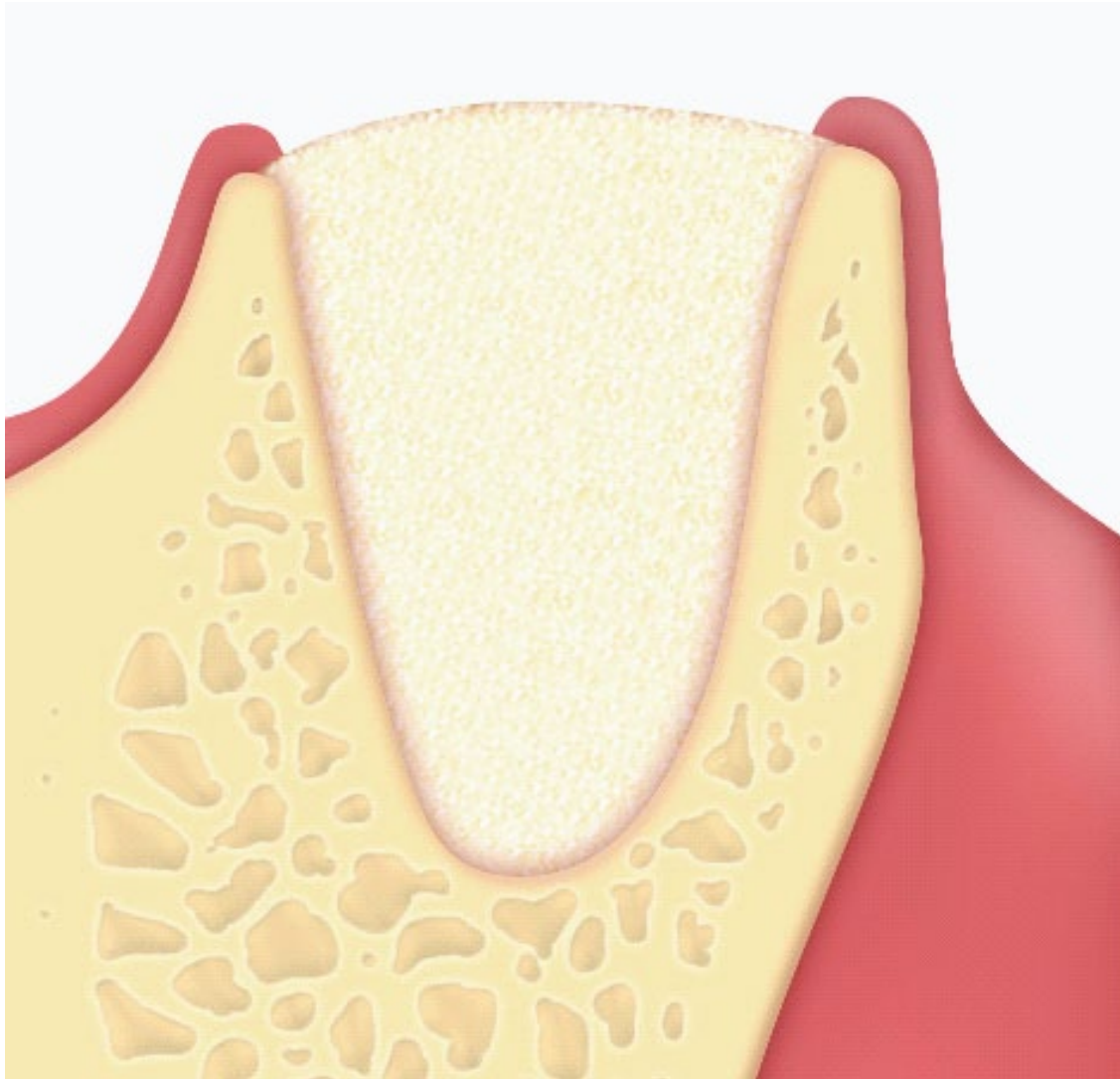
OsteoBiol®
by Tecnos

REGENERATION SCIENCE

INSPIRED BY NATURE



Regeneración alveolar



OsteoBiol[®]
by TecnoSS

REGENERATION SCIENCE

INSPIRED BY NATURE

Xenograft versus extraction alone for ridge preservation after tooth removal: a clinical and histomorphometric study

ABSTRACT

In order to allow a proper implant placement from both esthetics and function points of view, it is fundamental to preserve as much as possible the ridge bone volume immediately after tooth extraction. In order to obtain this, different biocompatible materials and autogenous bone have been used to treat the bone atrophy of the alveolar ridges.

The purpose of this randomized clinical trial was to compare the bone dimensional changes following tooth extraction with extraction plus ridge-preservation using cortico-cancellous porcine bone and a collagen membrane. Moreover, the Authors analyzed and compared the histologic and histomorphometric aspects of the extraction-alone sites to the grafted sites.

40 patients who required tooth extraction and implant placement were enrolled in this study and randomly assigned to the control group (EXT; extraction alone) or to the test group (RP; ridge-preservation procedure). In this last group, cortico-cancellous porcine bone (OsteoBiol® mp3®, Tecnos®, Giaveno, Italy) was packed into the socket and collagen membrane (OsteoBiol® Evolution, Tecnos®) was hydrated in sterile saline and trimmed to completely cover the socket.

The clinical and histologic evaluations showed significant differences between the two treatments. The implants were placed at all sites, although some implants in the extraction-alone group showed a buccal dehiscence that required guided bone regeneration procedures after implant insertion. The bone biopsies taken from the control and test sites 7 months after the surgical treatment and the histologic and histomorphometric analyses showed a significantly greater horizontal reabsorption ($4,3 \pm 0,8$ mm EXT vs. $2,5 \pm 1,2$ mm RP) and a greater ridge height reduction ($3,6 \pm 1,5$ mm) at the buccal side in the EXT group (RP: $0,7 \pm 1,4$ mm). The vertical change at the lingual sites was inferior in the ridge-preservation group. The biopsies harvested from the grafted sites revealed the presence of trabecular bone, which was highly mineralized and well structured. The amount of connective tissue was significantly higher in the extraction-alone group than in the ridge-preservation group.

CONCLUSIONS

This study showed that the almost complete incorporation of the cortico-cancellous particles in bone created a dense and hard tissue network in which the porcine bone particles were completely surrounded by vital bone. The results obtained suggest that the ridge-preservation approach using porcine bone in combination with collagen membrane can limit the resorption of hard tissue ridge after tooth extraction. Moreover, the new bone formation observed between the porcine bone particles might indicate that the biomaterial is osteoconductive and acts as a natural scaffold for new bone formation.

ALVEOLAR REGENERATION

016

A Barone¹⁻²
N Nicoli Aldini³
M Fini³
R Giardino³
JL Calvo Guirado⁴
U Covani¹⁻²

1 | Division of Dentistry, Versilia Hospital, Lido di Camaiore, Lucca, Italy.
2 | Oral Pathology and Medicine, School of Dental Medicine, University of Genoa, Genoa, Italy
3 | Experimental Surgery Department, Codivilla Putti Research Institute, Rizzoli Orthopedic Institute, Medical School, University of Bologna, Bologna, Italy
4 | School of Dental Medicine, University of Murcia, Murcia, Spain

ORIGINAL ARTICLE
Journal of Periodontology
2008 Aug;79(8):1370-7

Grafted with
BONE SUBSTITUTE
OsteoBiol® mp3®
MEMBRANE
OsteoBiol® Evolution

A randomized clinical trial to evaluate and compare implants placed in augmented vs. non-augmented extraction sockets. 3-year results

ABSTRACT

As the maintenance of long-term stability of implant solutions depends on the quality and quantity of the available alveolar bone supporting implantation, the preservation of the alveolar crest after tooth extraction is essential for the success of the rehabilitation. In order to evaluate the need for additional augmentation procedures at implant insertion, the aim of this randomized clinical study was to test the hypothesis of no difference in success rate, bone tissue remodelling and need for augmentation procedures for implants placed in grafted sites versus implants placed in naturally healed sites. 40 patients having at least one hopeless tooth were enrolled in the study. Extraction sockets allocated in the test group were grafted with cortico-cancellous porcine bone (OsteoBiol® mp3®, Tecnos®, Giaveno, Italy) and a collagen membrane (OsteoBiol® Evolution, Tecnos®) was used to completely cover the socket. In the control group no biomaterial was grafted. The ridge-preservation approach using porcine bone in combination with a collagen membrane significantly limited the reabsorption of hard tissue ridge after tooth extraction compared to extraction alone. All patients were followed up to 3 years. At the end of the study, the results were: one implant failed in the control group at the second stage of surgery (6 months after placement); one implant failed in the test group after 2 years of loading. The cumulative implant success rate at the 3-year follow-up visit reached 95% for both groups. No statistically significant differences were detected for marginal bone changes between the 2 groups.

CONCLUSIONS

Based on the results of the present investigation, it was concluded that implants placed into grafted extraction sockets exhibited a clinical performance similar to implants placed into non-grafted sites in terms of implant survival and marginal bone loss. However, the Authors underlined that *"it seems from these findings that extraction alone may lead to unpredictable healing patterns in which the remaining ridge does not often allow for an aesthetic and functional solution without the aid of an additional bone augmentation procedure simultaneously with implant placement."*

ALVEOLAR REGENERATION

053

A Barone^{1,2}
B Orlando^{1,2,3}
L Cingano⁴
S Marconcini^{1,5}
G Derchi^{2,3}
U Covani^{1,2}

1 | Department of Surgery, University of Pisa, Italy
2 | Istituto Stomatologico Tirreno, Versilia Hospital, Lido di Camaiore, Italy
3 | Nanoworld Institute, University of Genoa, Italy
4 | Department of Biophysical Dental and Medical Sciences and Technologies, University of Genova, Italy
5 | Department of Biophysical Sciences and Technologies, University of Genoa, Italy

ORIGINAL ARTICLE
Journal of Periodontology
2012 Jul;83(7):836-46

Grafted with
BONE SUBSTITUTE
OsteoBiol® mp3®
MEMBRANE
OsteoBiol® Evolution



ALVEOLAR REGENERATION

057

A Barone^{1,2}
M Ricci²
P Tonelli³
S Santini²
U Covani^{1,2}

1 | Department of Surgery, University of Pisa,
Pisa, Italy

2 | Istituto Stomatologico Toscana, Versilia General
Hospital, Lido di Camaiore (LU), Italy

3 | Department of Dentistry, University of Florence,
Florence, Italy

ORIGINAL ARTICLE

Clinical Oral Implants Research
2013 Nov;24(11):1231-7

Grafted with

BONE SUBSTITUTE

OsteoBiol® mp3®

MEMBRANE

OsteoBiol® Evolution

OsteoBiol®
by Tecnos

Tissue changes of extraction sockets in humans: a comparison of spontaneous healing vs. ridge preservation with secondary soft tissue healing

ABSTRACT

Different ridge preservation techniques are available in order to control the bone remodeling process after a tooth extraction. The aim of these procedures is the maintenance of the alveolar ridge dimensions. Guided bone regeneration techniques have shown better results when compared to tooth extraction alone and the aim of this study was to evaluate the changes of hard and soft tissues in post-extraction sockets treated with a ridge preservation procedure and to compare them with those of post-extraction sockets which had healed naturally. A total of 58 patients (29 controls, and 29 tests) were enrolled in this study and each patient was randomly allocated to a test group or control group using a specific software package. The control sites received suture without any grafting material. The test sites were grafted with cortico-cancellous porcine bone (OsteoBiol® mp3®, Tecnos®, Giaveno, Italy) and a collagen membrane (OsteoBiol® Evolution, Tecnos®). At baseline and at implant placement (i.e. at 4 months), vertical bone changes, horizontal bone changes and width of keratinized gingiva were evaluated. The control group showed vertical bone resorption of $1\pm0,7$ mm, $2,1\pm0,6$ mm at mesial and buccal sites, and $1\pm0,8$ mm and $2\pm0,73$ mm at distal and lingual sites respectively. With reference to the changes in horizontal dimension, an average resorption of $3,6\pm0,72$ mm was assessed. The test sites showed a vertical bone remodelling of $0,3\pm0,76$ mm, $1,1\pm0,96$ mm, at mesial and buccal sites, and $0,3\pm0,85$ mm, $0,9\pm0,98$ mm at distal and lingual sites respectively. The horizontal bone resorption at the test sites was $1,6\pm0,55$ mm.

CONCLUSIONS

The findings of this study let the Authors affirm that *"our data clearly indicate that the use of cortico-cancellous porcine substitute and resorbable membrane left exposed succeeded in reducing alveolar contour from remodeling when compared to non-treated extraction sockets. Furthermore, our research shows that the use of a ridge preservation technique may maintain ridge height when compared to tooth extraction alone"*.

Flap versus flapless procedure for ridge preservation in alveolar extraction sockets: a histological evaluation in a randomized clinical trial

ABSTRACT

Tooth extraction generally results in a loss of bone volume and remodelling of soft tissues and it is recommended to preserve the alveolar ridge in order to maintain the existing soft and hard tissues, in view of the subsequent rehabilitation treatments. In order to ensure an adequate architecture of the alveolar bone and soft tissues, necessary to obtain a functional and aesthetic prosthetic rehabilitation, the use of various techniques and biomaterials has been proposed over the years.

The aim of this study was to evaluate and compare the histological and histomorphometric features of two different procedures carried out in extraction socket grafting: the flapped and flapless technique. For the study, 34 patients were randomized to receive tooth extraction and ridge preservation with cortico-cancellous porcine bone (OsteoBiol® mp3®, Tecnos®, Giaveno, Italy), and a trimmed collagen membrane (OsteoBiol® Evolution, Tecnos®) with a full thickness mucoperiosteal flap and primary soft tissue closure (control group), or, with a flapless procedure and a secondary soft tissue closure (test group). The collagen membrane was covered with an advanced flap in the control sites, whereas no flap was raised and the collagen membrane was left exposed in the test sites.

In order to evaluate the percentages of newly formed bone, residual graft particles and marrow spaces, 3 months after ridge preservation bone core samples were harvested from both groups and processed to be observed under light microscopy.

Histological and histomorphometrical analyses did not report significant differences between the two groups and the mean percentages of newly formed bone, soft tissues and residual grafted particles were 22.5 and 22.5%, 59.3 and 59.4%, and 18.2 and 18.2% respectively for flap and flapless approach.

CONCLUSIONS

The present randomized clinical trial was performed to evaluate clinical and histological differences between flap versus flapless ridge preservation procedure. As no differences in the histologic and histomorphometric analysis were found, the Authors concluded that *"this study supported the hypothesis of the non-detrimental effect of collagen membrane exposure on bone regeneration during the ridge preservation procedures with a flapless approach"*.

ALVEOLAR REGENERATION

073

A Barone^{1,2,3}
V Borgia^{1,3}
U Covani^{1,3}
M Ricci^{1,3}
A Piattelli⁴
G Iezzi⁴

1 | Department of Surgical, Medical, Molecular and Critical Area Pathology, University of Pisa, Pisa, Italy
2 | AOU of Pisa, Pisa, Italy
3 | Tuscan Stomatologic Institute, Versilia General Hospital, Lido di Camaiore, Italy
4 | Dental School, University of Chieti-Pescara, Chieti, Italy


ORIGINAL ARTICLE

Clinical Oral Implants Research
2015 Jul;26(7):806-13

Grafted with

BONE SUBSTITUTE
OsteoBiol® mp3®

MEMBRANE
OsteoBiol® Evolution



ALVEOLAR REGENERATION

074

A Barone¹
M Ricci²
GE Romanos³
P Tonelli⁴
F Alfonsi²
U Covani^{1,2}

1 | Department of Surgical, Medical, Molecular and
Critical Area Pathology, University of Pisa, Pisa, Italy
2 | Tuscan Dental Institute, Versilia General Hospital,
Lido di Camaiore, Italy
3 | School of Dental Medicine, Stony Brook University,
Stony Brook, NY, USA
4 | Department of Dentistry, University of Florence,
Florence, Italy

ORIGINAL ARTICLE
Clinical Oral Implants Research
2015 Jul;26(7):823-30

Buccal bone deficiency in fresh extraction sockets: a prospective single cohort study

ABSTRACT

After a tooth extraction, architectural changes occur in soft and hard alveolar tissues and these may jeopardize the aesthetic success of implant-supported restorations.

In this prospective single cohort study, the Authors aimed to evaluate the use of xenograft and collagen membranes in treating full or partial buccal bone defects of fresh extraction sockets in the aesthetic zone, which had a partial or complete deficiency of the buccal bone plate and that had been treated with a ridge preservation procedure and delayed implant placement. In 33 patients requiring tooth extraction in the anterior maxillary area and showing a complete or partial buccal bone plate deficiency (more than 2 mm) cortico-cancellous porcine bone (OsteoBiol® mp3®, Tecnos®, Giaveno, Italy) and platelet-rich fibrin (PRF) with a collagen membrane (OsteoBiol® Evolution, Tecnos®) were used to graft the extraction sockets, and the membranes were left exposed to the oral cavity with a secondary soft tissue healing.

The parameters investigated were: width of keratinized mucosa, facial soft tissue levels, clinical bone changes (measured with a clinical splint), implant and prosthesis failures, and peri-implant marginal bone changes.

All treated sites allowed the placement of implants and at the time of flap elevation, the augmented tissues seemed to be well vascularized, the presence of residual graft particles seemed well integrated into the augmented sites and all implants were stable after placement. The facial soft tissue level increased over time, the bone level showed an improvement and in the palatal area no bone changes were observed. No implant failed during the entire observation period.

CONCLUSIONS

Based on the findings from this study, the Authors concluded that *"within the limit of this prospective cohort study, ridge preservation showed an adequate regeneration of the buccal bone plate and stability of the facial soft tissue level for extraction sockets with large buccal bone defects. Implant installation and prosthetic restoration showed favourable outcomes after 1 year of this ongoing study. These preliminary findings should be confirmed by a longer follow-up study"*.

Grafted with

BONE SUBSTITUTE
OsteoBiol® mp3®

MEMBRANE
OsteoBiol® Evolution

Dimensional alterations of extraction sites after different alveolar ridge preservation techniques - a volumetric study

ABSTRACT

A tooth extraction always represents a trauma after which there is a horizontal and vertical volume loss of both hard and soft tissues. In order to reduce these volumetric changes, the placement of biomaterials within the fresh extraction socket has been suggested. As the data reported in literature are not conclusive, the aim of this randomized controlled clinical study was to evaluate to which extent a filler or a soft tissue socket seal contributes to ridge preservation. 30 patients were enrolled in the study and, after tooth extraction, were randomly assigned to the following treatments: Tx1 - xenogenic bone substitute (pre-hydrated collagenated cortico-cancellous porcine bone; OsteoBiol® mp3®, Tecnos®, Giaveno, Italy) and free gingival graft; Tx2 - free gingival graft alone; Tx3 - xenogenic bone substitute (OsteoBiol® mp3®, Tecnos®) without gingival graft; Tx4 - no further treatment (control). The dimensional changes were evaluated by means of impressions taken at baseline (before tooth extraction) and 4 months after surgery, with subsequent pouring of cast models. These ones were then optically scanned and analysed using digital imaging analysis. Healing of all treatment groups was uneventful and all groups displayed contour shrinkage at the buccal aspect.

Statistically significant differences were found between Tx1 and Tx4 as well as Tx2 and Tx4. A significant positive influence of the free gingival graft on the maintenance of the ridge width was recorded ($p < 0.001$).

CONCLUSIONS

The results of this clinical study show that the investigated alveolar ridge preservation techniques were not able to prevent soft tissue contour alterations entirely after tooth extraction. Because measurements were based on master models, no statements can be made as to whether the documented horizontal volume resorption was caused by loss of soft tissue or underlying bone. The use of a free gingival graft covering the extraction socket was beneficial for maintaining soft tissue volume, but more studies including a higher number of patients or sites are needed to further investigate these findings.

ALVEOLAR REGENERATION

084


T Thalmair¹
S Fickl²
D Schneider⁴
M Hinze¹
H Wachtel^{1,3}

1 | Private Institute for Periodontology and Implantology, Munich, Germany
2 | Department of Periodontology, Julius-Maximilians University, Würzburg, Germany
3 | Department of Prosthodontics, Dental School, Free University of Berlin, Berlin, Germany
4 | Clinic of Fixed and Removable Prosthodontics and Dental Material Science, University of Zurich, Zurich, Switzerland

ORIGINAL ARTICLE

Journal of Clinical Periodontology
2013 Jul;40(7):721-7

Grafted with
BONE SUBSTITUTE
OsteoBiol® mp3®



OsteoBiol®
by Tecnos

ALVEOLAR REGENERATION

087

A Barone^{1,2}

P Toti^{1,2}

A Quaranta³

F Alfonsi^{1,2}

A Cucchi⁴

JL Calvo Guirado⁵

B Negri⁵

R Di Felice⁶

U Covani^{1,2}

1 | Department of Surgical, Medical, Molecular and Critical Area Pathology, University of Pisa, Pisa, Italy

2 | Tuscan Stomatologic Institute, Versilia General Hospital, Lido di Camaiore (LU), Italy

3 | Department of Odontology and Specialized Clinical Sciences (DISCO), Marche Polytechnic University, Torrette di Ancona, Italy

4 | Department of Surgery, University of Verona, Verona, Italy

5 | Department of Implantology, University of Murcia, Murcia, Spain

6 | Private Practice, Ascoli Piceno, Italy

ORIGINAL ARTICLE

Clinical Oral Implants Research
2016 Nov;27(11):e105-e115

Volumetric analysis of remodelling pattern after ridge preservation comparing use of two types of xenografts. A multicentre randomized clinical trial

ABSTRACT

This paper is a report of the results of a multicentre, single-blind, prospective and randomized clinical trial, performed by the Authors in order to analyse and compare the volumetric changes after ridge preservation procedures using two different biomaterials. Moreover, they evaluated the associations between outcome variables and pristine three-dimensional aspects of the ridges.

For the study, 38 patients subjected to single-tooth alveolar ridge preservation were selected and randomly allocated to each experimental group. The extraction sockets of the coll group were grafted with pre-hydrated collagenated cortico-cancellous porcine bone, with graft particle size between 600 and 1000 μm (OsteoBiol® mp3®, Tecnos®, Giaveno, Italy). In cort group, the extraction sockets were grafted with cortical porcine bone alone, with particle size between 600 and 1000 μm (OsteoBiol® Apatos, Tecnos®). A collagen membrane (OsteoBiol® Evolution, Tecnos®) was used to completely cover the socket, left intentionally exposed to the oral cavity and stabilized with the use of sutures. A secondary soft tissue healing was obtained for all experimental sites. By means of scanned plaster casts, an analysis of volumes and areas was performed, and all measured variables were statistically compared.

Intragroup analyses at 3 months revealed that the two biomaterials showed similar behaviours with a minor loss in volume and ridge surface. Intergroup analysis at 3-month survey revealed that volume resorption of the coll group was significantly lower than that of the cort group.

CONCLUSIONS

Considering the 3rd month analysis, in their conclusions the Authors affirm that *“coll group showed a significantly lower reduction of ridge volume and a significantly smaller shrinkage of the basal area when compared to the cort group; moreover, the coll group experienced a smaller superior surface shrinkage when compared to the cort group, even though no significance was evaluated”*.

Grafted with

BONE SUBSTITUTE

OsteoBiol® Apatos

OsteoBiol® mp3®

MEMBRANE

OsteoBiol® Evolution

PAG 56

Abstract author: Cristina Rodighiero, dental journalist, free publication, not for resale. Printed by Tecnos® Dental s.r.l.



Immediate, immediate-delayed (6 weeks) and delayed (4 months) post-extractive single implants: 4-month post-loading data from a randomised controlled trial

ABSTRACT

The aim of this study was to compare the clinical outcome of single implants placed immediately after tooth extraction with an immediate approach (70 patients), an immediate-delayed placement approach (implants placed 6 weeks after tooth extraction - 70 patients), and with a delayed placement approach (implants placed after 4 months of extraction and socket healing - 70 patients). After implant placement and the measurement of the gap between the bony wall and the neck of the implant with a periodontal probe, the operator reconstructed all poorly preserved sockets and partially preserved sockets in the aesthetic areas with a bone substitute. The bone substitute used was a sticky paste made of 600 to 1000 μ m pre-hydrated collagenated cortico-cancellous granules of porcine origin, properly mixed with collagen gel in a sterile syringe (OsteoBiol® mp3®, Tecnos®, Giaveno, Italy). The grafted area was then covered with a resorbable membrane derived from equine pericardium (OsteoBiol® Evolution, Tecnos®). The membrane was trimmed and adapted to cover the entire socket and at least 2 mm of the surrounding crestal bone, and fixed using titanium tacks.

Implants inserted with at least 25 Ncm torque were left to heal unloaded for 4 months, whereas those inserted with less than 25 Ncm were left to heal unloaded for 6 months. Temporary crowns were delivered and were to be replaced by definitive ones after 4 months. Outcome measures were crown and implant failures, complications, peri-implant marginal bone level changes, aesthetics and patient satisfaction.

No statistically significant differences for failures, complications and patient satisfaction were observed when placing single implants immediately, 6 weeks or 4 months after tooth extraction; nevertheless failures and complications were more frequent for immediate and immediate-delayed placed implants. Bone level changes were similar between the different procedures, but the aesthetics showed better results for immediate and immediate-delayed implants.

CONCLUSIONS

When interpreting the results of this study, the Authors recommend to take into consideration that immediate and immediate-delayed post-extractive implant sites were augmented. As they underline, *"it is known that site preservation procedures are able to preserve the dimension of the site better compared to when these procedures are not implemented. The immediate or early placement of the implant in a post-extractive site might also contribute and partly preserve the width and height of the surrounding tissues. In order to better understand these mechanisms, more trials with larger sample sizes are needed"*.

ALVEOLAR REGENERATION

099

P Felice¹
G Zucchelli¹
G Cannizzaro²
C Barausse¹
M Diazzi³
A Trullenque-Eriksson^{4,5}
M Esposito⁶

1 | Department of Biomedical and Neuromotor Sciences, Unit of Periodontology and Implantology, University of Bologna, Bologna, Italy

2 | Private Practice, Pavia, Italy

3 | Private Practice, Bologna, Italy

4 | Folkandvården Sylte, Trollhättan, Sweden

5 | Institute of Dentistry, Barts, The London School of Medicine and Dentistry, Queen Mary University of London, London, UK

6 | Department of Biomaterials, The Sahlgrenska Academy at Göteborg University, Göteborg, Sweden

ORIGINAL ARTICLE

European Journal of Oral Implantology
2016;9(3):233-247

Grafted with

BONE SUBSTITUTE
OsteoBiol® mp3®

MEMBRANE
OsteoBiol® Evolution



ALVEOLAR REGENERATION

101

A Barone^{1,2}
P Toti^{2,3}
S Marconcini^{2,3}
G Derchi^{2,3}
M Saverio^{2,3,4}
U Covani^{2,3}

1 | Unit of Oral Surgery and Implantology,
Department of Surgery, University of Geneva,
Switzerland, Genève, Switzerland
2 | Department of Surgical, Medical, Molecular and
Critical Area Pathology, University of Pisa, Pisa, Italy
3 | Tuscan Stomatologic Institute, Versilia General
Hospital, Lido di Camaiore (LU), Italy
4 | Azienda Ospedaliero-Universitaria Pisana, Pisa,
Italy

ORIGINAL ARTICLE

Int J Oral and Maxillofacial Implants
2016;31(6)

Grafted with

BONE SUBSTITUTE

OsteoBiol® mp3®

MEMBRANE

OsteoBiol® Evolution

OsteoBiol®
by Tecnos

Esthetic outcome of implants placed in fresh extraction sockets by clinicians with or without experience: A medium-term retrospective evaluation

ABSTRACT

Immediate implant placement is often a challenge for the clinician, due to the large number of factors playing a role in the aesthetic outcome of dental implants. Therefore, it is necessary a treatment strategy aimed to reduce the risk of soft tissue recession with immediate implants, including bone fillers with a low substitution rate, flapless surgery, and connective tissue graft. The present study aimed to evaluate and compare the aesthetic clinical outcome of implants placed in fresh extraction sockets up to 3 years after implant placement, performed by experienced versus non-experienced surgeons (residents in implant dentistry). The evaluation focused on the peri-implant tissue remodelling and the subjective aesthetic and functional outcome of implants placed in fresh extraction sockets. To do this, a retrospective chart review study of patients treated at the Versilia General Hospital, and subjected to dental implant positioning for fixed prosthetic rehabilitation between February 2009 and April 2011, was conducted. Treated independent post-extraction areas were divided into two groups according to the operator's experience: expert versus nonexpert group. After tooth extraction, debridement of the extraction socket was performed, and then the implant bed was prepared. Any vertical bone defect or residual gap between the implant surface and bone wall was augmented with cortico-cancellous porcine bone (OsteoBiol® mp3®, Tecnos®, Giaveno, Italy). A resorbable membrane (OsteoBiol® Evolution, Tecnos®) with a cross-mattress suture was left exposed to the oral cavity, seeking a secondary soft tissue healing. Patients treated by non-expert clinicians showed greater bone loss and soft tissue recession than those treated by experienced senior surgeons. Moreover, the esthetic self-evaluation of patients confirmed more positive results for the experienced group.

CONCLUSIONS

The findings of this study suggest that esthetic outcomes can be compromised by the inexperience of surgeons, especially when the implants are placed in esthetic areas. Consequently, the Authors conclude that *"if clinicians plan immediate implant placement in the anterior area, it is recommended that this type of technique be carried out by experienced operators"*.



ALVEOLAR REGENERATION

106

A Barone^{1,3}

P Toti^{2,3}

A Quaranta⁴

F Alfonsi¹

A Cucchi⁵

B Negri⁶

R Di Felice⁷

S Marchionni^{2,3}

JL Calvo Guirado^{2,3}

U Covani^{2,3}

U Nannmark⁸

1 | Unit of Oral Surgery and Implantology,
Department of Surgery, University of Geneva,
Switzerland

2 | Department of Surgical, Medical, Molecular and
Critical Area Pathology, University of Pisa, Italy

3 | Tuscan Dental Institute, Versilia General Hospital,
Lido di Camaiore (LU), Italy

4 | Department of Dentistry, University of West
Australia, Perth, Australia

5 | Department of Surgery, University of Verona,
Verona, Italy

6 | Department of Implantology, University of
Murcia, Spain

7 | Private Practice, Ascoli Piceno, Italy

8 | Department of Oral & Maxillofacial Surgery, the
Sahlgrenska Academy Gothenburg University,
Gothenburg, Sweden

ORIGINAL ARTICLE

Journal of Clinical Periodontology
2017 Feb;44(2):204-214

Grafted with

BONE SUBSTITUTE

OsteoBiol® Apatos
OsteoBiol® mp3®

MEMBRANE

OsteoBiol® Evolution

PAG 60

OsteoBiol®
by Tecnos

Tissue changes after ridge preservation with two xenografts. Preliminary results from a multicenter randomized controlled clinical trial.

ABSTRACT

Ridge preservation procedures can counteract the tissue changes occurring after tooth loss. The aim of this randomized controlled trial was to compare and evaluate the clinical and histological outcomes of extraction sockets grafted with cortical porcine bone (OsteoBiol® Apatos, Tecnos®, Giaveno, Italy) (*cort*-group) to those grafted with collagenated cortico-cancellous porcine bone (OsteoBiol® mp3®, Tecnos®) (*coll*-group) both covered with a collagen membrane (OsteoBiol® Evolution, Tecnos®) left exposed and fresh extraction sockets which healed naturally (*nat*-group).

The two different xenografts were also compared to each other to determine their respective efficacy in preserving the alveolar ridge dimensions following tooth extraction. The anatomical measurements were taken at baseline and at 3 months after tooth extraction. The following variables were registered to the nearest millimeter: vertical bone changes; buccal-lingual width; histomorphometric parameters such as newly formed bone (NFB), non-mineralized tissues (NMT) and residual graft particles percentages (RGP).

The grafted sites showed a significant ($P<0.0001$) lower vertical bone loss at buccal and lingual/palatal aspects than that registered at the no-grafting sites. Moreover, the grafted groups behaved significantly better than the non-grafted group in terms of horizontal bone resorption. The *cort*- and *coll*-groups had a horizontal bone loss of 1.33 ± 0.71 mm and 0.93 ± 1.25 mm, respectively, while the *nat*-group had a horizontal bone loss of 3.60 ± 0.72 mm. No statistically significant differences were registered between the grafted groups for any of the variables, except for vertical bone loss at the lingual/palatal aspect ($P=0.0039$).

CONCLUSIONS

The present study showed that porcine bone, resorbable membrane and a flapless approach were more effective in controlling the bone changes after tooth extraction when compared to no grafting. The ridge preservation procedures had significantly better outcomes when compared to natural healing. The biomaterials did not differ for maintenance of bone width; even though, the bone height seemed to be better preserved with the cortical porcine bone.

Based on these findings, the Authors affirm: "Alveolar ridge preservation with cortical or collagenated cortico-cancellous porcine bone is an effective way to maintain the ridge dimensions after tooth extraction compared to spontaneous healing, though a complete prevention of remodeling is not achievable irrespective of the biomaterial employed. No significant differences were found between the two pertaining to the ridge width. Furthermore, no significant differences regarding the histomorphometric analysis were registered between the two grafted groups".

Molecular, cellular and pharmaceutical aspects of filling biomaterials during the management of extraction sockets

ABSTRACT

After a tooth extraction, both hard and soft tissues undergo dimensional changes and the aim of grafting and/or guided bone regeneration procedures is to counteract these changes by using different biomaterials and surgical techniques. In this article, the Authors reviewed the clinical, histological, volumetric and molecular results reported in different studies, so to evaluate which are the best surgical techniques and biomaterials for ridge preservation procedures.

Among the biomaterials tested for bone augmentation procedures, the one made of cortico-cancellous granules of porcine bone showed to be very similar to human mineral bone. Its natural micro-porous consistency is supposed to facilitate new bone tissue formation in defect sites and accelerate the regeneration process. Moreover, the studies evaluated in this review reported that this biomaterial is gradually resorbable and able to preserve the original graft shape and volume (osteoconductive property). Other important observations about porcine bone are related to the integration of collagenated porcine bone graft with the new bone and its capability to support the new bone formation when used in extraction sockets. Among the advantages of porcine bone, osteoconductivity and absence of adverse reaction and inflammatory response were mentioned. The histomorphometrical analysis of the reviewed studies showed that the percentage of new bone tissue was 22.5% of the total bone.

CONCLUSIONS

In their review, the Authors pointed out that cortico-cancellous porcine bone satisfied the characteristics of osteoconductivity and volume maintenance during the healing period, allowing new bone formation and reabsorption of the xenograft, without any signs of inflammatory cells.

ALVEOLAR REGENERATION

107

F Alfonsi¹
V Borgia²
G Iezzi³
A Piattelli³
U Covani²
P Tonelli¹
A Barone²

1 | Department of Public Health, Section of Dentistry, University of Florence, Florence, Italy
2 | Unit of Oral Surgery and Implantology, School of Dental Medicine, Department of Surgery, University of Geneva, Switzerland
3 | Department of Medical, Oral and Biotechnological Sciences, Dental School, University G. D'Annunzio of Chieti-Pescara, Chieti, Italy

ORIGINAL ARTICLE

Current Pharmaceutical Biotechnology
2017;18(1):64-75

Grafted with

BONE SUBSTITUTE
OsteoBiol® Gen-Os®
OsteoBiol® mp3®
OsteoBiol® Apatos

MEMBRANE
OsteoBiol® Evolution

BARRIER - BONE SUBSTITUTE
OsteoBiol® Lamina



ALVEOLAR REGENERATION

111

M Esposito¹

G Zucchelli²

G Cannizzaro³

L Checchi²

C Barausse²

A Trullenque-Eriksson^{4,5}

P Felice²

1 | Department of Biomaterials, The Sahlgrenska Academy at Goteborg University, Goteborg, Sweden

2 | Department of Biomedical and Neuromotor Sciences, University of Bologna, Bologna, Italy

3 | Department of Dentistry, Vita-Salute University, IRCCS San Raffaele, Milan, and private practices in Pavia and Milan, Italy

4 | Folkh andv rden Sylte, Trollh ttan, Sweden

5 | The Institute of Dentistry, Barts and The London School of Medicine and Dentistry, Queen Mary's Hospital, London, UK

ORIGINAL ARTICLE

European Journal of Oral Implantology
2017;10(1):11-26

Grafted with

BONE SUBSTITUTE

OsteoBiol® mp3®

MEMBRANE

OsteoBiol® Evolution

OsteoBiol®
by Tecnos

Immediate, immediate-delayed (6 weeks) and delayed (4 months) post-extractive single implants: 1-year post-loading data from a randomised controlled trial


ABSTRACT

Nowadays there are different approaches with reference to timing of implant positioning, each one having its own advantages and limits. So, it would be useful to know whether a better clinical outcome could be achieved by placing delayed implants after bone healing, or by waiting for a few weeks to allow soft tissues to heal, or by placing implants immediately after tooth extraction. The aim of this RCT was to compare the clinical outcome of single implants placed immediately after tooth extraction with implants placed 6 weeks after tooth extraction (immediate-delayed placement), and with implants placed after 4 months of extraction and socket healing (delayed placement). In total, 210 patients were treated: 70 patients received immediate post-extractive implants, 70 patients received immediate-delayed implants at 6 weeks, and 70 patients received delayed implants after 4 months of healing, according to a parallel group design. In case of a large gap between the bony wall and the neck of the implant, patients of the immediate and immediate-delayed group had the socket grafted with a bone substitute made of a sticky paste made of 600-1000 µm pre-hydrated collagenated corticocancellous granules of porcine origin, properly mixed with collagen gel in sterile syringe (OsteoBiol® mp3®, Tecnos®, Giaveno, Italy). The grafted area was then covered with a resorbable membrane derived from equine pericardium (OsteoBiol® Evolution (fine), Tecnos®). The same grafting approach was used also for the sockets randomised to delayed implants if poorly preserved or in the aesthetic areas (from second upper to second upper premolars).

Outcome measures were crown and implant failures, complications, peri-implant marginal bone level changes, aesthetics assessed using the pink aesthetic score (PES), and patient satisfaction recorded by blinded assessors. Patients were followed up to 1 year post-loading.

CONCLUSIONS

No statistically significant differences for failures, complications and patient satisfaction were observed when placing single implants immediately, 6 weeks or 4 months after tooth extraction. Failures were more frequent at immediate and immediate-delayed placed implants and bone level changes were similar between the different procedures, but aesthetics results were better at immediate and immediate-delayed implants. With reference to this last outcome, the Authors underline that *"there are two plausible explanations for the present findings, which could work synergistically: delayed sites were not subjected to any bone preservation procedures unless in aesthetic areas or if severely damaged, as is often carried out in clinical practice. It is known that site preservation procedures are better able to preserve the site dimensions than not implementing any. The immediate or early placement of the implant in a post-extractive site might also contribute to partly preserve the width and height of the surrounding tissues. In order to better understand these mechanisms, more trials with large sample sizes are needed"*.



ALVEOLAR REGENERATION

114

A Barone¹

P Toti^{2,3}

GB Menchini-Fabris^{2,3}

G Derchi^{2,3}

S Marconcini^{2,3}

U Covani^{2,3}

1 | Unit of Oral Surgery and Implantology,
Department of Surgery, University of Geneva,
Genève, Switzerland

2 | Department of Surgical, Medical, Molecular and
Critical Area Pathology, University of Pisa, Pisa, Italy

3 | Tuscan Dental Institute, Fortis Dental Center, Forte
dei Marmi, Italy

ORIGINAL ARTICLE

Clinical Implant Dentistry and Related Research
2017;19(4):750-759

Grafted with

BONE SUBSTITUTE

OsteoBiol® mp3®
OsteoBiol® Apatos

Extra oral digital scanning and imaging superimposition for volume analysis of bone remodeling after tooth extraction with and without 2 types of particulate porcine mineral insertion: a randomized controlled trial

ABSTRACT

In case of progressive tissue and volume loss with dimensional changes of the alveolar ridge contour, it has been demonstrated that incorporation of bone substitute material into the extraction socket can minimize the edentulous ridge volume loss or maximize the bone formation within the healing area. This technique, called socket grafting or "alveolar ridge preservation" (ARP), showed to be effective. The aim of this multi-center single-blind randomized control trial was to test the effectiveness of socket grafting with 2 biomaterials (cortical or pre-hydrated collagenated cortico-cancellous porcine bone) covered with a resorbable barrier in maintaining contour stability of the extraction area when compared to control extraction sockets that had a natural healing. The observation was performed by means of a laser scanner that provided the possibility of 3-dimensional evaluation to be performed on patients' dental arches plaster cast models. Following tooth extraction, 55 patients were assigned to their treatment group using a random sequencing: 15 patients (*cort*) were grafted with cortical porcine bone (particle size 600-1000 μ m, OsteoBiol® Apatos, Tecnos®, Giaveno, Italy); 15 patients (*coll*) were grafted with collagenated cortico-cancellous porcine bone (particle size 600-1000 μ m, OsteoBiol® mp3®, Tecnos®); 25 patients (*nat*) had natural healing without grafting.

At the 4-month intergroup analysis, the test groups (cortical or pre-hydrated collagenated cortico-cancellous porcine material) seemed to behave significantly better than the naturally-healing group in terms of volume and contour conservation. No differences were seen, however, between the 2 test groups, although the volume loss and linear height reduction seemed to slightly favour the collagenated material.

CONCLUSIONS

Based on the results of the present randomized trial, Authors concluded that "the present investigation attested that post-extractive sockets grafted with either cortical or pre-hydrated collagenated cortico-cancellous porcine material covered with a resorbable collagen membrane showed reduced bone loss when compared to naturally-healing sockets. Moreover, the 2 grafting materials were not able to preserve the alveolar crest, and a reduction close to 30% in the estimates was registered after healing".

Regenerative properties of collagenated porcine bone grafts in human maxilla: demonstrative study of the kinetics by synchrotron radiation microtomography and light microscopy

ABSTRACT

As bone dimensional changes normally occur after tooth extraction, the management of extraction sockets needs a particularly careful attention by the clinician. After tooth extraction, in order to reduce the soft and hard tissue loss, preservation of the alveolar ridge volume is recommended and different types of biomaterial have been used to graft fresh extraction sockets and the majority of them showed favourable clinical outcomes. The aim of the present study was to analyze the regenerative potential of collagenated cortico-cancellous (OsteoBiol® mp3®, TecnoSS®, Giaveno, Italy) bone by synchrotron radiation X-ray micro-CT and histology in order to quantitatively investigate the kinetics of healing in post-extraction sockets. To the best of the authors' knowledge, this is the first study on kinetics of bone regeneration using cortico-cancellous porcine bone substitutes, which are biomaterials developed with a structure similar to the human bone. Specifically, OsteoBiol® mp3® is a pre-hydrated collagenated heterologous cortico-cancellous bone mix made of 600 – 1000 µm thick granules (90 vol%) and collagen gel (10 vol%).

Ridge preservation was performed on 21 patients using a flapless approach and a secondary soft tissue closure. Extraction sockets were filled and slightly condensed with cortico-cancellous porcine bone (mp3®), and a trimmed collagen membrane (OsteoBiol® Evolution, TecnoSS®) was used to completely cover the socket. At the time of implant surgery, the bone cores were harvested and evaluated by micro-CT and histology. Both micro-CT and histology confirmed the good performances of the collagenated cortico-cancellous porcine bone as substitute for the preservation of human maxillary post-extraction sockets.

CONCLUSIONS

As the Authors concluded: *“the OsteoBiol® mp3® bone substitute, 12 months after grafting, was shown to offer better biomechanical performances than the spontaneously healed bone after the same period. Indeed, an increased density, due to a significant increase of the trabecular number, seems to guarantee an improved strength of the socket, starting point favorable to the success of the next implant”.*

ALVEOLAR REGENERATION

115

A Giuliani¹
G Iezzi²
S Mazzoni¹
A Piattelli²
V Perrotti²
A Barone^{3,4}

1 | Department of Clinical Sciences, Polytechnic University of Marche, Ancona, Italy

2 | Department of Medical, Oral and Biotechnological Sciences, University of Chieti-Pescara, Italy

3 | Department of Surgery, Unit of Oral Surgery and Implantology, School of Dental Medicine University of Geneva, Geneva, Switzerland

4 | Department of Surgical, Medical, Molecular Pathology and of the Critical Area, University of Pisa, Italy

ORIGINAL ARTICLE

Clinical Oral Investigations
2017;22(1):505-513

Grafted with

BONE SUBSTITUTE
OsteoBiol® mp3®

MEMBRANE
OsteoBiol® Evolution



ALVEOLAR REGENERATION

122

V Checchi¹
P Felice²
G Zucchelli²
C Barausse²
M Piattelli³
R Pistilli⁴
G Grandi⁵
M Esposito⁶

1 | Department of Medicine, Surgery and Health Sciences, University of Trieste, Trieste, Italy

2 | Department of Biomedical and Neuromotor Sciences, Unit of Periodontology and Implantology, University of Bologna, Bologna, Italy

3 | Department of Medical, Oral and Biotechnologies Sciences, University G. d'Annunzio, Chieti-Pescara, Italy

4 | Oral and Maxillofacial Unit, San Camillo Hospital, Rome, Italy

5 | Department of Obstetrics, Gynaecology and Pediatrics, University of Modena and Reggio Emilia, Italy

6 | Department of Biomaterials, The Sahlgrenska Academy at Göteborg University, Sweden

ORIGINAL ARTICLE

European Journal of Oral Implantology
2017; 10(3): 263-278

Grafted with

BONE SUBSTITUTE

OsteoBiol® Gen-Os®

MEMBRANE

OsteoBiol® Evolution

OsteoBiol®
by Tecnos

Wide diameter immediate post-extractive implants vs delayed placement of normal-diameter implants in preserved sockets in the molar region: 1-year post-loading outcome of a randomised controlled trial

ABSTRACT

In case of tooth loss, in order to minimise the risk of implant failures and complications, delayed implant placement after complete socket healing is generally preferred, usually associated with different ridge preservation procedures, ranging from soft tissue grafts to autogenous or bone substitutes grafts. As it would be useful to know if it is possible to have similar or better clinical outcomes by placing immediately wide diameters implants in post-extractive sites, the aim of this single-centre randomised controlled trial (RCT) was to compare the effectiveness of 6.0 to 8.0 mm-wide diameter implants placed immediately after tooth extraction, with conventional diameter implants placed in preserved sockets after 4 months of healing in molar sites. In the delayed group, the sockets were loosely packed with a mixture of cancellous and cortical porcine-derived bone granules with a granulometry of 250 to 1000 μm (OsteoBiol® Gen-Os® Tecnos®, Giaveno, Italy). In order to cover the socket, a resorbable collagen membrane derived from equine pericardium (OsteoBiol® Evolution, Tecnos®) was trimmed and adapted on it. Included in the outcomes measures there were the peri-implant marginal bone level changes. Marginal bone levels at implant insertion (after bone grafting) were 0.04 mm for immediate implants and 0.11 mm for the delayed ones, and this was statistically significantly different. One year after loading, the loss was on average 1.06 mm in the immediate group and 0.63 in the delayed group, with a statistically significant difference. From an aesthetic point of view, the total PES score was statistically significantly better at delayed implants both at 4 months (9.65 ± 1.62 in the immediate group and 10.44 ± 1.47 in the delayed group) and at 1 year (9.71 ± 2.71 in the immediate group and 10.86 ± 1.37 in the delayed group). With reference to failures, 5 implants out of 47 failed in the immediate group (10.6%) and 2 out of 44 in the delayed one (4.6%), with a difference not statistically significant. About complications, in the immediate group 10 patients reported complications vs 4 patients in the delayed group (difference not statistically significant). To be noted that 7 patients (14%) in the immediate group developed vestibular bone dehiscence from 3 months after implant placement to 9 months postloading.

CONCLUSIONS

The present study supports the notion that post-extractive immediately loaded implants could be at a higher risk of failure than delayed implants, as confirmed by other RCTs. The results show ridge preservation and delayed conventional implants placement yielded better aesthetic outcomes compared to immediate placement of larger diameter implants. At 1 year after loading, immediate implants lost 0.43 mm more bone than delayed implants and this difference was statistically significant.



Comparison of magnesium-enriched hydroxyapatite and porcine bone in human extraction socket healing: a histologic and histomorphometric evaluation.

ABSTRACT

After tooth extraction, the physiological reduction of alveolar height and width may cause problems with implants placement, especially in the anterior upper arch where bone volume preservation is essential for both biological and aesthetic reasons. In order to counteract bone resorption in fresh sockets and avoid invasive ridge augmentation procedures, the use of several biomaterials has been proposed. Thanks to its excellent biocompatibility and bioactivity, hydroxyapatite is widely used in bone grafting and it has a good potential as a scaffold for bone tissue engineering. The aim of this study was to compare the use of synthetic magnesium-enriched hydroxyapatite (MHA) with that of a xenogenic bone substitute consisting of cortico-cancellous porcine bone (PB) (OsteoBiol® Apatos, Tecnos®, Giaveno, Italy), in fresh sockets by means of histological and histomorphometric analyses. Histological examinations revealed newly formed bone, biomaterial particles, connective tissue and an absence of inflammatory cells in all treated sites.

CONCLUSIONS

The histological findings from the present study showed that cortico-cancellous PB and MHA could be used successfully for ridge preservation. Moreover, they both resulted safe and biocompatible. The authors concluded that *“within the limits of this study, the results showed similar biological behaviour with respect to bone formation and resorption for magnesium-enriched hydroxyapatite and porcine bone used for socket preservation”*.

ALVEOLAR REGENERATION

123

R Crespi¹
P Capparrè¹
E Gherlone¹


¹ | Department of Dentistry, Vita Salute University, San Raffaele Hospital, Milan, Italy

ORIGINAL ARTICLE

Int Journal of Oral and Maxillofacial Implants
2011 Sep-Oct;26(5):1057-62

Grafted with

BONE SUBSTITUTE
OsteoBiol® Apatos



S Corbella¹
S Tascherie¹
L Francetti¹
R Weinstein¹
M Del Fabbro¹

¹ | Dental Department of Biomedical, Surgical and
Dental Sciences, Università degli Studi di Milano,
Milan, Italy; IRCCS Istituto Ortopedico Galeazzi,
Milan, Italy

ORIGINAL ARTICLE

Int Journal of Oral and Maxillofacial Implants
2017 Sep/Oct;32(5):1001–1017

Grafted with

BONE SUBSTITUTES

OsteoBiol® Gen-Os®

OsteoBiol® mp3®

OsteoBiol® Apatos

MEMBRANE

OsteoBiol® Evolution

Histomorphometric results after postextraction socket healing with different biomaterials: a systematic review of the literature and meta-analysis

ABSTRACT

In this article, the authors present a systematic review of the literature with data about histomorphometric outcomes after alveolar socket healing following tooth extraction with or without the placement of a bone substitute material. The primary outcome was the percentage of new bone formation. Secondary outcomes were percentage of biomaterial, connective tissue and non-mineralized tissue still present as measured through histomorphometric analysis of samples.

A total of 802 papers were screened and after the application of the inclusion and exclusion criteria, 40 articles were included in the quantitative synthesis and 11 were included in the meta-analysis of comparative studies. In 16 studies, no bone substitute material was used. Bovine bone (BB) was used in 14 studies; allograft (AG) was used in 5 studies; porcine bone (PB) was used in 4 studies; hydroxyapatite (HA), was used in 6 studies and HA enriched with magnesium in 4 studies; freeze-dried bone allograft (FDBA) was used in 4 studies; calcium sulphate (CS) was used in 4 studies, beta-tricalcium phosphate (β -TCP) was used in 2 studies and other biomaterials were used in 7 studies.

The meta-analysis of the results showed that the use of BB is associated with a lower proportion of vital bone compared to ungrafted sockets, while PB and magnesium-enriched HA seemed to enhance bone formation. Sites grafted with AG showed a proportion of new bone comparable to that of sites that did not receive any bone substitute.

CONCLUSIONS

Within the limits of this review, from the results it is possible to conclude that there is no evidence for the superiority of a given biomaterial over the others in terms of new bone formation. With reference to new bone volume, comparative studies reported that BB caused a reduced proportion of new bone volume (NBV), while PB and magnesium-enriched HA induced a significantly higher amount of NBV, compared to sites healed without bone substitutes.

How effective is collagen resorbable membrane placement after partially impacted mandibular third molar surgery on postoperative morbidity? A prospective randomized comparative study

ABSTRACT

This was a prospective, randomized controlled study on the two methods (primary closure and secondary closure) proposed for wound closure in case of mandibular third molar (3 M) surgery. The study sample included patients with no history of medical illness or medication that could influence wound healing. They were randomly assigned to three groups: the secondary closure group (SC), with partial closure of the extraction site to allow secondary healing; the primary closure group (PC), involving total closure of the extraction site for primary healing; and the membrane based primary closure group (MBPC), involving total closure of the extraction site by sliding the flap and using a collagen membrane positioned to extend 3–4 mm beyond the margin of the bone defect. The aim of the study was to evaluate the incidence of postoperative complications and analyze swelling, mouth opening, and pain. With reference to pain, its scores were generally slightly better in the SC group than in the PC and MBPC groups, but with no statistically significant difference between the 3 groups ($p > 0.05$) except between SC and MBPC on the second day ($p = 0.014$). The swelling recorded on postoperative days 2 and 7 was lower in the SC group than in the PC ($p = 0.046$ and 0.000) and in MBPC ($p = 0.005$ and 0.002) groups, respectively, with no significant differences between the PC and MBPC groups ($p > 0.05$). Even if mouth opening showed a statistically significant difference between the three groups at day 2 ($p = 0.000$), at day 7 there were no statistically significant differences between the three groups ($p = 0.093$) and the same was registered also for trismus scores.

CONCLUSIONS

According to the results of the present study, swelling and mouth opening seem to be better in case of a secondary closure. Primary closure and primary closure using the collagen membrane are relatively similar in terms of immediate postoperative discomfort. Anyway, the use of resorbable collagen membrane showed clinically satisfactory results and the absence of alveolitis and the minimal wound dehiscence in the primary closure using the collagen membrane suggests that membranes can support primary healing in terms of wound healing.

ALVEOLAR REGENERATION

126

A Kilinc¹
M Ataol¹

¹ | Department of Oral and Maxillofacial Surgery,
Faculty of Dentistry, Ataturk University, Erzurum,
Turkey

ORIGINAL ARTICLE
BMC Oral Health
2017 Oct 5;17(1):126

Grafted with
MEMBRANE
OsteoBiol® Evolution



ALVEOLAR REGENERATION

127

G Troiano¹
K Zhurakivska¹
L Muzio¹
L Laino²
M Cicciù³
L Lo Russo¹

¹ Department of Clinical and Experimental Medicine,
Foggia University, Foggia, Italy
² | Multidisciplinary Department of Medical- Surgical
and Dental Specialties, Second University of Naples,
Naples, Italy
³ | Department of Human Pathology, School of
Dentistry, University of Messina, Messina, Italy

ORIGINAL ARTICLE

J Periodontol. 2018;89:46–57

Grafted with

BONE SUBSTITUTES

OsteoBiol® Gen-Os®

OsteoBiol® mp3®

OsteoBiol® Apatos

MEMBRANE

OsteoBiol® Evolution

OsteoBiol® Lamina

PAG 70

OsteoBiol®
by Tecnos

Combination of bone graft and resorbable membrane for alveolar ridge preservation: a systematic review, meta-analysis, and trial sequential analysis

ABSTRACT

It is well known that, after tooth extraction, the alveolar ridge undergoes remodelling and resorption, with the undesired result of a reduction of the height and width of the residual ridge. Consequently, alveolar ridge preservation (ARP) techniques are advocated in order to counteract these events and a variety of grafting materials has been tested in the postextractive socket. The aim of this systematic review was to analyze evidence regarding potential benefits of ARP procedures performed with allogenic/xenogenic grafts in combination with a resorbable membrane coverage in comparison with spontaneous healing. Consequently, in this paper seven studies comparing the use of a bone substitute combined with a resorbable membrane in the test group and spontaneous healing of the extraction socket in the control group were included. Materials used in the included studies were the following: six studies reported use of xenogenic grafting materials consisting of cortico-cancellous porcine bone, collagenated cortico-cancellous porcine bone, and bovine bone mineral associated with a collagen membrane, whereas one study reported the use of FDBA combined with a collagen membrane. In all studies, the control group was characterized by spontaneous healing. Horizontal ridge width reduction (HRWR) and vertical ridge height reduction (VRHR) were investigated as primary outcomes and volume changes (VC) as a secondary outcome. Meta-analysis revealed that the combination therapy resulted in a lower rate of resorption for both HRWR (−2.19 mm, 95% confidence interval [CI]: −2.67 to −1.71 mm) and VRHR (−1.72 mm, 95% CI: −2.14 to −1.30 mm).

CONCLUSIONS

According to the results of the meta-analysis, the evidence currently available in the literature is strong enough to conclude that filling postextraction sockets with a bone substitute covered by a resorbable membrane results in a lower rate of resorption, both in vertical and horizontal dimensions, compared with spontaneous healing. The Authors concluded that *“further studies should be directed to compare use of different bone substitutes and membranes and investigate potential and significant variability related to them, as well as to flap design”*.

Influence of the presence of alveolar mucosa at implants: a histological study in humans

ABSTRACT

In case of tooth loss, in order to minimise the risk of implant failures and complications, delayed implant placement after complete socket healing is generally preferred, usually associated with different ridge preservation procedures, ranging from soft tissue grafts to autogenous or bone substitutes grafts. As it would be useful to know if it is possible to have similar or better clinical outcomes by placing immediately wide diameters implants in post-extractive sites, the aim of this single-centre randomised controlled trial (RCT) was to compare the effectiveness of 6.0 to 8.0 mm-wide diameter implants placed immediately after tooth extraction, with conventional diameter implants placed in preserved sockets after 4 months of healing in molar sites. In the delayed group, the sockets were loosely packed with a mixture of cancellous and cortical porcine-derived bone granules with a granulometry of 250 to 1000 μm (OsteoBiol® Gen-Os® Tecnos®, Giaveno, Italy). In order to cover the socket, a resorbable collagen membrane derived from equine pericardium (OsteoBiol® Evolution, Tecnos®) was trimmed and adapted on it. Included in the outcomes measures there were the peri-implant marginal bone level changes. Marginal bone levels at implant insertion (after bone grafting) were 0.04 mm for immediate implants and 0.11 mm for the delayed ones, and this was statistically significantly different. One year after loading, the loss was on average 1.06 mm in the immediate group and 0.63 in the delayed group, with a statistically significant difference. From an aesthetic point of view, the total PES score was statistically significantly better at delayed implants both at 4 months (9.65 ± 1.62 in the immediate group and 10.44 ± 1.47 in the delayed group) and at 1 year (9.71 ± 2.71 in the immediate group and 10.86 ± 1.37 in the delayed group). With reference to failures, 5 implants out of 47 failed in the immediate group (10.6%) and 2 out of 44 in the delayed one (4.6%), with a difference not statistically significant. About complications, in the immediate group 10 patients reported complications vs 4 patients in the delayed group (difference not statistically significant). To be noted that 7 patients (14%) in the immediate group developed vestibular bone dehiscence from 3 months after implant placement to 9 months post-loading.

CONCLUSIONS

The present study supports the notion that post-extractive immediately loaded implants could be at a higher risk of failure than delayed implants, as confirmed by other RCTs. The results show ridge preservation and delayed conventional implants placement yielded better aesthetic outcomes compared to immediate placement of larger diameter implants. At 1 year after loading, immediate implants lost 0.43 mm more bone than delayed implants and this difference was statistically significant.

ALVEOLAR REGENERATION


147

Y Nakajima^{1,2}
A Piattelli³
G Iezzi³
N F Mesa⁴
M Ferri⁴
D Botticelli^{2,4}

1 | Department of Oral Implantology, Osaka Dental University, Osaka, Japan
2 | ARDEC Academy, Ariminum Odontologica, Rimini, Italy
3 | Department of Medical, Oral and Biotechnological Sciences, University of Chieti-Pescara, Chieti, Italy
4 | Corporación Universitaria Rafael Núñez, Cartagena de Indias, Colombia

ORIGINAL ARTICLE
Implant Dentistry, Volume 27,
Number 2 2018

Grafted with
BONE SUBSTITUTE
OsteoBiol® Gen-Os®
MEMBRANE
OsteoBiol® Evolution



ALVEOLAR REGENERATION

152

B Chandrasekaran¹
N Suresh²
S Muthusamy²

1 | Academic Unit of Craniofacial Clinical Care,
Faculty of Dentistry, AIMST University, Kedah,
Malaysia

2 | Academic Unit of Primary and Preventive dentistry,
Faculty of Dentistry, AIMST University, Kedah,
Malaysia

ORIGINAL ARTICLE

The Chinese Journal of Dental Research
2017;20(4):231-234

Grafted with

BONE SUBSTITUTES
OsteoBiol® Gen-Os®

Platelet-Rich Fibrin with bone grafts for regeneration of bony defect following extraction of supernumerary teeth: a case report

ABSTRACT

In case of abnormalities during tooth development, supernumerary teeth can occur as hyperdontic variants that exhibit diverse nature in terms of prevalence among races and location in human jaws. In this article, the Authors present a case report of partly erupted supernumerary teeth in regions 35 and 36 with its surgical management and regeneration of residual bony defect. In a 41-year-old male patient the presence of two supernumerary teeth was confirmed through occlusal and periapical radiographs. After a complete clinical examination, the surgical removal of supernumerary teeth was planned. The bone defect that ensued after removal was significantly large and, as a bony dehiscence was observed in relation to the lingual aspect of tooth 35 and the mesio lingual aspect of tooth 36, a combination of bone grafts (autograft, allograft (Puros, Zimmer Dental, CA, USA), xenograft (Osteobiol® Gen Os®, Tecnos®, Giaveno, Italy) and platelet-rich fibrin (PRF) was placed to augment the bony defect. Over the 1-year period post operatively, gingival recession was seen on the grafted site; anyway, bone was present until two-thirds of the roots radiographically, suggesting adequate bone fill.

CONCLUSIONS

In this approach, the Authors used a combination of autograft with cortico-cancellous bone in the form of allograft and xenograft, ensuring not only sufficient bone fill, but also provided osteogenic, osteoinductive and osteoconductive effects to the surgical site. Hence, the Authors feel that this approach can be used as a viable option for management of such situations.

Extraction socket healing in humans after ridge preservation techniques: comparison between flapless and flapped procedures in a randomized clinical trial

ABSTRACT

Socket preservation procedures performed after tooth extraction allow maintaining soft and hard tissues architecture adequate for implant placement. The aim of this study is to investigate the effect of two surgical procedures, named flap and flapless, on the horizontal and vertical socket remodelling and the keratinized gingiva width. All sockets are treated with a xenograft and a collagen membrane.

Sixty-four patients, requiring at least one single premolar or molar tooth extraction and an implant-supported restoration, are included and randomly allocated to either test (flapless, with secondary soft tissue healing) or control (flap elevation and primary soft tissue closure) groups. In the test group, extraction sockets are augmented with cortico-cancellous porcine bone (OsteoBiol® mp3® Tecnos®, Giaveno, Italy) and the graft is covered by a collagen membrane (OsteoBiol® Evolution). The collagen membrane is secured by sutures and left intentionally exposed to the oral cavity. Extraction sockets allocated to the control group receive a full-thickness mucoperiosteal flap procedure with two releasing incisions and augmentation with the same cortico-cancellous porcine bone covered by a collagen membrane; here the buccal flap is advanced coronally to guarantee soft tissue primary closure. After three months, the clinical outcomes of the two procedures are measured and analyzed using appropriate statistical tests. Comparing the two socket preservation techniques, statistically significant differences are registered for the output variables: changes in the width of keratinized gingiva, changes in the bucco-lingual width, and vertical bone changes at four sites, with P values of <0.001, <0.001, and 0.0105, respectively.

CONCLUSIONS

The results of this study might support the hypothesis that the flapless technique better preserves the hard tissue dimensions than the primary closure; moreover, the flapless procedure gives an increase in keratinized gingiva as an additional benefit. On the other hand, the flapped technique seems to result in smaller vertical bone resorption on the buccal aspect than the flapless technique.

ALVEOLAR REGENERATION

157

A Barone^{1,2}
P Toti^{1,2,3}
A Piattelli⁴
G Iezzi⁴
G Derchi^{1,2}
U Covani^{1,2}

1 | Department of Surgery, Medical, Molecular, and Critical Area Pathology, University of Pisa, Pisa, Italy
2 | Tuscan Stomatologic Institute, Versilia General Hospital, Lido di Camaiore, Italy
3 | Private practice, Camaiore, Italy
4 | Dental School, University of Chieti-Pescara, Chieti, Italy

ORIGINAL ARTICLE
Journal of Periodontology
2014 jan;85(1):14-23

Grafted with

BONE SUBSTITUTE
OsteoBiol® mp3®

MEMBRANE
OsteoBiol® Evolution



ALVEOLAR REGENERATION

168

M Kivovics¹
BT Szabó²
O Németh¹
N Tari³
F Döri³
P Nagy⁴
C Dobó-Nagy²
G Szabó⁵

- 1 | Department of Community Dentistry, Semmelweis University, Budapest, Hungary
2 | Department of Oral Diagnostics, Semmelweis University, Budapest, Hungary
3 | Department of Periodontology, Semmelweis University, Budapest, Hungary
4 | Department of Pathology and Experimental Cancer Research, Semmelweis University, Budapest, Hungary
5 | Department of Oro-Maxillofacial Surgery and Stomatology, Semmelweis University, Budapest, Hungary

ORIGINAL ARTICLE

Int. J. Oral Maxillofac. Surg.
2017; 46: 250–260

Grafted with

BONE SUBSTITUTE

OsteoBiol® Gen-Os®

MEMBRANE

OsteoBiol® Evolution

OsteoBiol®
by TecnoSS

Microarchitectural study of the augmented bone following ridge preservation with a porcine xenograft and a collagen membrane: preliminary report of a prospective clinical, histological, and micro-computed tomography analysis

ABSTRACT

It is universally known that the loss of teeth results in the alveolar ridge resorption and atrophy. When the atrophy is severe, it creates unfavourable conditions for implant positioning, needing a proper ridge augmentation. Therefore, following tooth extraction, it is advisable to adopt one of the several techniques and biomaterials described in the literature so to preserve the alveolus. In literature there are reports of the successful application of several bone graft materials in ridge preservation. One of these materials is a xenograft of porcine origin that has recently been studied. It is a particulated, high-porosity, cortico-cancellous xenograft, maintaining the structure and composition of the natural collagen and hydroxyapatite. The aim of this prospective study was to investigate the integration of porcine xenografts used in ridge preservation by histological and micro-CT analysis, focusing on whether socket grafting interferes with natural bone healing. The patients enrolled in the study were categorized into two study groups: in the test group (group 1; nine patients) patients underwent socket preservation, while the sockets in the control group (group 2; eight patients) were left to heal without the use of socket preservation techniques. In group 1, the cortico-cancellous porcine bone graft (OsteoBiol® Gen-Os®, TecnoSS®, Giaveno, Italy) was packed into the socket and a porcine collagen membrane (OsteoBiol® Evolution) was used as occlusive barrier. After a 6-month healing period, bone core biopsy samples were obtained and implants were placed in all sites. Histological analysis of the bone core biopsy samples obtained from the augmented sites of group 1 revealed that particles of the bone substitute material were surrounded by newly formed trabecular bone in 8 out of the 12 cases. Histological analysis of the 12 bone core biopsy samples obtained from the non-augmented sites in group 2 revealed healthy bone formation in the extraction sockets. The findings of the micro-CT analysis were consistent with those of the histological analysis.

CONCLUSIONS

After a 6-month healing period, the bone volume was sufficient for implant placement in all sites. The analyses performed revealed that the particles of the xenograft interfere with bone healing in the augmented sites. However, socket preservation using a combination of porcine xenografts and collagen membrane successfully maintained the vertical and horizontal dimensions of the ridge. Therefore, the Authors concluded that *“in this study, socket preservation with the combination of a porcine xenograft and collagen membrane to maintain the bone volume of four-wall bone defects prior to implantation was utilized successfully”*.

Clinical outcomes of implants placed in ridge-preserved versus nonpreserved sites: a 4-year randomized clinical trial

ABSTRACT

After tooth extraction, alveolar bone undergoes remodelling resulting in dimensional changes, which can complicate implant insertion. In order to limit dimensional changes, alveolar ridge preservation procedures using different grafting materials are commonly used. As the long-term effect of ridge preservation on implant success rate is still unclear, the aim of the present randomized clinical study was to evaluate the survival, success, and the aesthetic outcomes of implants placed in extraction sockets. In the study, 90 patients in need for a single premolar/molar tooth extraction and an implant treatment were randomly distributed among 3 groups: spontaneous healing (ctrl), ridge preservation with cortical porcine bone (OsteoBiol® Apatos, Tecnos®, Giaveno, Italy) (cort) and ridge preservation with collagenated corticocancellous porcine bone (OsteoBiol® mp3®, Tecnos®) (coll). In the two test groups, the sockets were grafted with the chosen biomaterial and a collagen membrane (OsteoBiol® Evolution, Tecnos®) was placed under the interdental papillae. The collagen membrane was exposed to the oral cavity.

Three months after tooth extraction, at re-entry, implants were placed (BT Evo; Biotec, Vicenza, Italy). Marginal bone levels were recorded on digital intraoral periapical radiographs, the assessment of the Pink Esthetic Score (PES) was performed on digital photographs. Forty-two patients out of 90 (initial cohort study) completed the entire follow-up of 4 years. Cumulative survival and success rates for all implants were 100% at the 4-year evaluation. With reference to the marginal bone loss, there were no significant differences between the 2 grafting materials, but it was significantly greater in the nongrafted sites (P value < .001). At the 4-year evaluation, the PES resulted significantly better in the cort group than in the coll and ctrl ones.

CONCLUSIONS

From the results, it is evident that ridge preservation was more effective than natural healing in preserving marginal bone and better aesthetic outcomes were achieved. Although none of the grafting materials in this study could entirely preserve the pristine ridge contour of the post extractive socket, cortical porcine bone showed the best clinical outcomes in maintaining the vertical bone dimension. On the other hand, the collagenated corticocancellous porcine bone showed the best outcome in maintaining the horizontal dimension.

ALVEOLAR REGENERATION

169

S Marconcini¹
E Giammarinaro²
G Derchi¹
F Alfonsi¹
U Covani¹
A Barone³

1 | Department of Surgical, Medical, Molecular and Critical Area Pathology, University of Pisa, Pisa, Italy
2 | Department of Dentistry, Tuscan Stomatologic Institute, Lido di Camaiore, Italy
3 | Department of Surgery, Unit of Oral Surgery and Implantology, University-Hospital at Geneva, School of Dental Medicine, Geneva, Switzerland

ORIGINAL ARTICLE
Clin Implant Dent Relat Res
2018;1-9

Grafted with

BONE SUBSTITUTE
OsteoBiol® mp3®
OsteoBiol® Apatos

MEMBRANE
OsteoBiol® Evolution