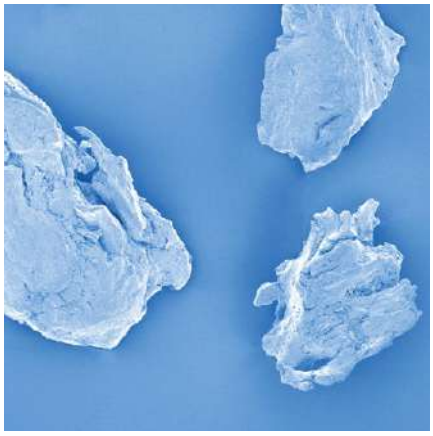
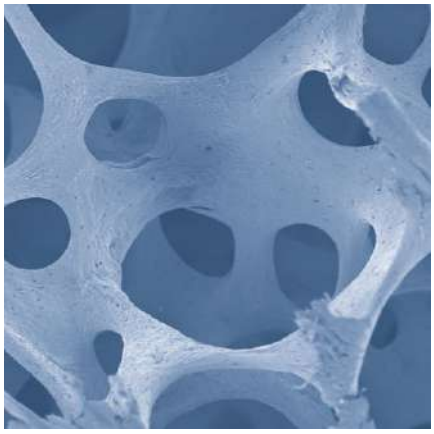
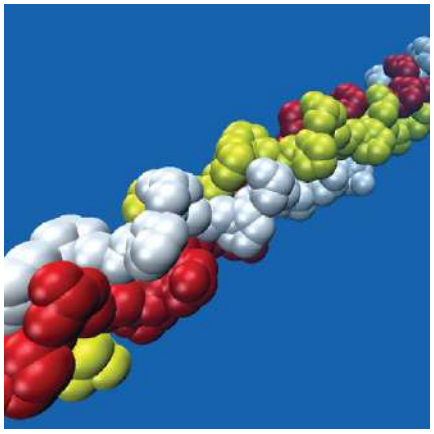
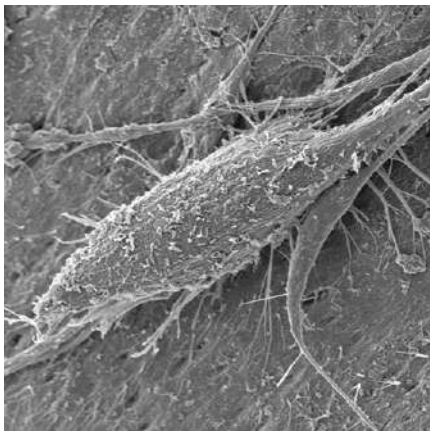
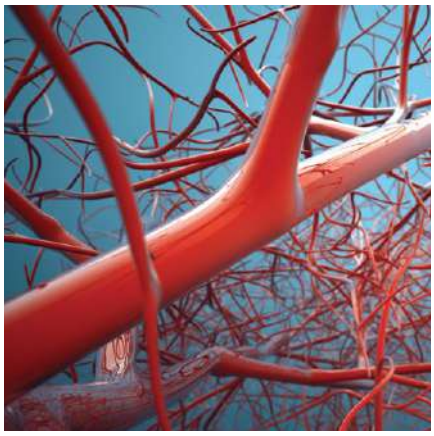
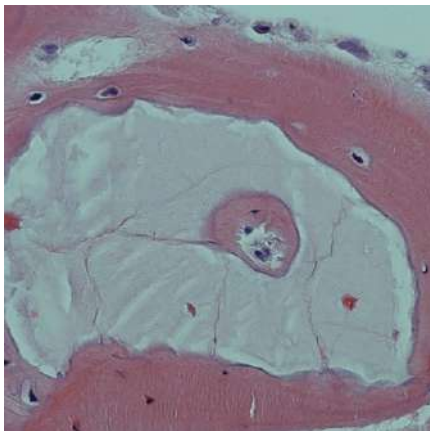

SCIENTIFIC ABSTRACTS

INTERNATIONAL PUBLICATIONS ON OSTEOBIOL® BIOMATERIALS

OsteoBiol®
by Tecnoss

REGENERATION SCIENCE

INSPIRED BY NATURE

Elevación de seno por acceso lateral

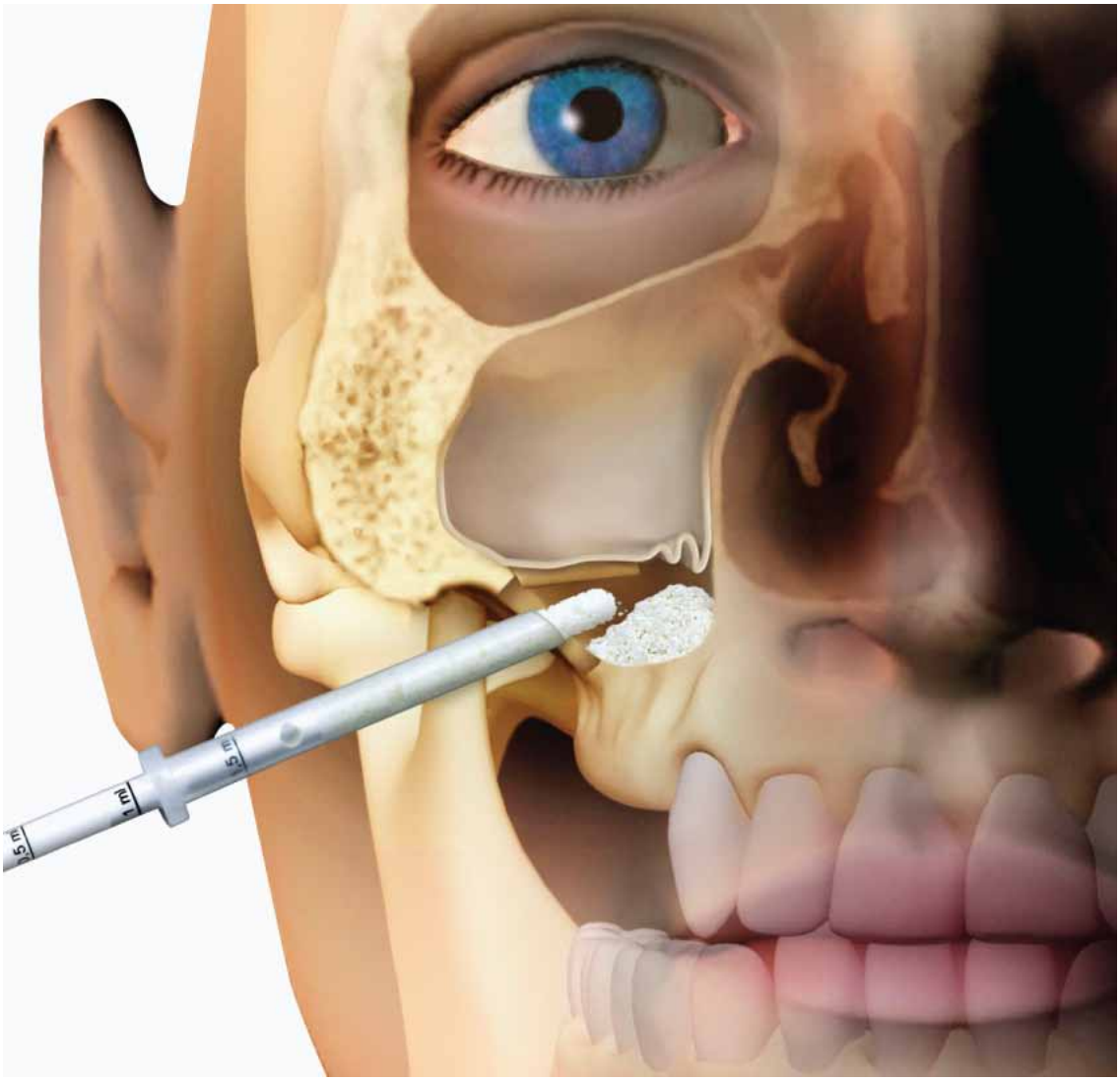

OsteoBiol®
by Tecnoss

REGENERATION SCIENCE

INSPIRED BY NATURE

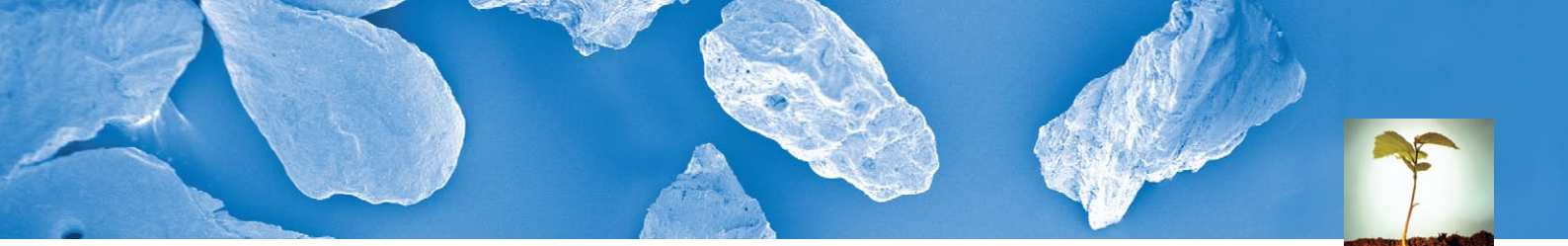

OsteoBiol® by Tecnoss

Osteotomy and membrane elevation during the maxillary sinus augmentation procedure. A comparative study: piezoelectric device vs. conventional rotative instruments

A Barone[1]
S Santini[1]
S Marconcini[1]
L Giacomelli[2]
E Gherlone[3]
U Covani[1]

1 | Unit of Oral Pathology and Medicine, University of Genova, Genova, Italy
2 | Nanoworld Institute, CIRNNOB and Biophysics Division, University of Genova, Genova, Italy
3 | University of Milan, Hospital San Raffaele, Milan, Italy

ABSTRACT

Sinus lift is generally considered to be a safe surgical procedure for the maxillary sinus floor augmentation with a low prevalence of complications. Anyway, in case of a sinus membrane perforation, it is no more possible to guarantee the graft stability and its vascularization, jeopardizing the maturation and mineralization of the bone graft. Moreover, the presence of a large sinus membrane perforation allows migration of the graft to the respiratory mucosa and its bacterial contamination.

The aim of this randomized-controlled clinical trial was to compare two treatment procedures for the surgical access (osteotomy and sinus membrane elevation) to the maxillary sinus by means of piezoelectric device and conventional instruments during the maxillary sinus floor augmentation procedures.

A total of 13 patients (10 females and 3 males) who required a bilateral maxillary sinus floor elevation for implant-prosthetic rehabilitation were selected. A within-patient control study was carried out. The osteotomy for sinus access was performed on one side of the maxilla using the piezosurgery (test sites) and on the other side using conventional rotary diamond burs (control sites).

Once the sinus membranes were elevated to obtain the requested volume for bone grafting, all the maxillary sinuses were grafted using 100% cortico-cancellous pig bone particles (OsteoBiol® *mp3*®, Tecnoss®, Giaveno, Italy). The bony sinus windows were covered with a reabsorbable collagen membrane (OsteoBiol® *Evolution*, Tecnoss®).

CONCLUSIONS

All patients had an uneventful healing and no signs or symptoms of maxillary sinus disease were observed after the augmentation surgical procedures.

With reference to the comparison between the two surgical procedures, none of the differences observed between the two groups reached a level of significance.

Within the limits of the present study, the Authors concluded that *"piezosurgery and conventional instruments did not show any differences in the clinical parameters investigated for the maxillary sinus floor elevation"*.

ORIGINAL ARTICLE
Clinical Oral Implants Research
2008 May;19(5):511-5

Grafted with

BONE SUBSTITUTE
OsteoBiol® *mp3*®

MEMBRANE
OsteoBiol® *Evolution*

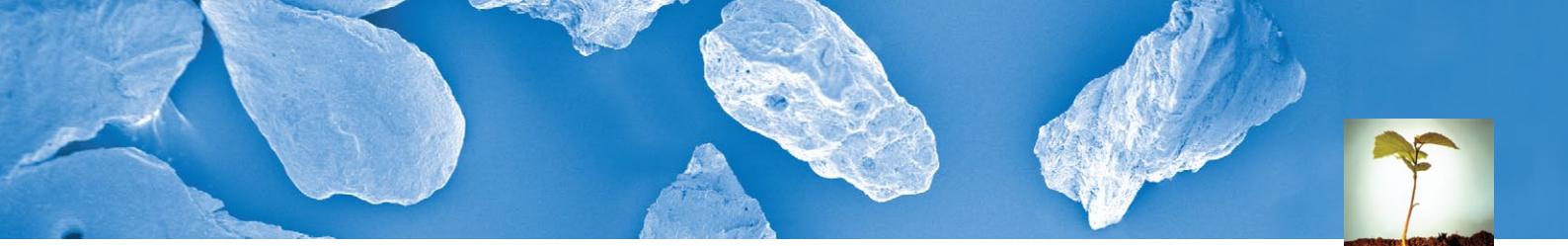

OsteoBiol® by Tecnoss

A collagenated porcine bone substitute for augmentation at Neoss implant sites: a prospective 1-year multicenter case series study with histology

L Pagliani[1,2]
P Andersson[1,3,4]
M Lanza[1,5]
A Nappo[6]
D Verrocchi[1,4,5]
S Volpe[1,7]
L Sennerby[1,3,8]

1 | The Feltre/Fiera Di Primiero Implant Research Group, Feltre, Italy
2 | Private practice, Milano and Legnano, Italy
3 | Private practice, Feltre, Italy
4 | Private practice, Fiera Di Primiero, Italy
5 | Private practice, San Dona Di Piave, Italy
6 | Private practice, Salerno, Italy
7 | Private practice, Rome, Italy
8 | Department of Biomaterials, Institute Clinical Sciences, Sahlgrenska Academy, University of Gothenburg, Sweden

ABSTRACT

It is well known that the presence of localized defects and/or small amounts of bone below the maxillary sinus can compromise implant placement. In such situation, in order to achieve predictable results, it is necessary to perform specific bone augmentation techniques. Different bone substitutes and barrier membranes are commonly used for the augmentation of localized defects and of the maxillary sinus floor and the aim of this study was to evaluate from a clinical and histological point of view a porcine bone (PB) substitute used for augmentation of the alveolar crest or the maxillary sinus floor prior to or in conjunction with implant placement. The biomaterials used were two types of collagenated bone of porcine origin (OsteoBiol® *Gen-Os*® or OsteoBiol® *mp3*®, Tecnoss®, Giaveno, Italy), two types of collagen gel (OsteoBiol® *Gel 40* or OsteoBiol® *Gel 0*, Tecnoss®), and two types of membranes (OsteoBiol® *Evolution Fine* or OsteoBiol® *Lamina Soft X-fine*, Tecnoss®). 19 patients were treated, with a total of 34 implants (Neoss Ltd., Harrogate, UK) placed. Implants were followed with implant stability measurements at placement and abutment connection, and with intraoral radiographs at abutment connection and after at least 1 year of loading. A biopsy for histology and morphometry was taken at the first re-entry operation. The results show that all but one procedure resulted in successful augmentation, with an overall procedure success rate of 94,7% and 90% for maxillary sinus floor augmentations. The histological examination showed the formation of new bone at the PB surface, forming bridges between particles and between particles and preexisting bone. The presence of scalloped resorption lacunae and new osteons inside the particles indicated ongoing resorption/remodeling of the particles.

CONCLUSIONS

The clinical cases presented in this study showed that collagenated PB could effectively be used for bone augmentation of various defects in all the 19 patients. The study included different defects and treatment strategies because the Authors decide to evaluate the use of the PB in consecutive patients with different needs as usually dealt with in everyday practice. This study showed good clinical results when using a PB substitute and barrier membranes for augmentation of the alveolar crest and maxillary sinus and the histology revealed osteoconductive properties of the material and also indicated osteoclastic resorption.

ORIGINAL ARTICLE
Clinical Implant Dentistry and Related Research
2012 Oct;14(5):746-58

Grafted with

BONE SUBSTITUTES
OsteoBiol® *Gen-Os*®
OsteoBiol® *Gel 40*
OsteoBiol® *mp3*®

MEMBRANE
OsteoBiol® *Evolution*

BARRIER -
BONE SUBSTITUTE
OsteoBiol® *Lamina*

COLLAGEN GEL
OsteoBiol® *Gel 0*

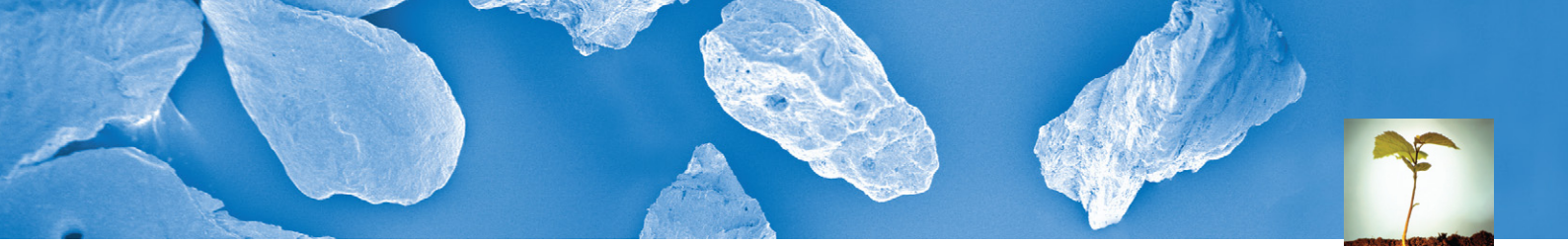

OsteoBiol® by Tecnoss

Zygomatic implant placement in conjunction with sinus bone grafting: the "extended sinus elevation technique." A case-cohort study

M Hinze[1]
L Vrielinck[2]
T Thalmair[1]
H Wachtel[3]
W Bolz[1]

1 | Private practice, Private Institute of Periodontology and Implantology, Munich, Germany
2 | Private practice, Department of Oral and Maxillofacial Surgery, Hospital East Limburg, Genk, Belgium
3 | Department of Restorative Dentistry, Charité - Medical University Berlin, Germany; Private Institute of Periodontology and Implantology, Munich, Germany

ORIGINAL ARTICLE
Oral and Craniofacial Tissue Engineering
2011;1:188-97

ABSTRACT

In case of edentulous patients with an extremely atrophied maxilla, the implant-prosthetic rehabilitation represents a challenge for clinicians. As a matter of fact, the progressive bone resorption in the posterior region, the widening of the sinuses and the anterior alveolar bone resorption can dramatically reduce the possibility to perform a standard implant-prosthetic treatment. The introduction of the zygomatic implants made it possible for clinicians to perform immediate implant placement without bone augmentation for the treatment of such patients. However, although zygomatic implant insertion may have a number of advantages, existing clinical data have shown that the placement of zygomatic implants increases the risk of postoperative complications related to the sinus. The purpose of this cohort study was to introduce a modified surgical technique for the placement of zygomatic implants aiming to minimize the risk of biologic complications. The selected 10 patients, all with an extremely atrophied maxillae, were planned to be treated with one to four zygomatic implants in conjunction with sinus bone grafting. After the integrity of the sinus membrane was confirmed, the established sinus cavity was augmented with a bone graft material (OsteoBiol® *mp3*®, Tecnoss®, Giaveno, Italy) and the augmented area was covered with a resorbable barrier membrane (OsteoBiol® *Soft Cortical Lamina*, Tecnoss®) to prevent soft tissue ingrowth into the sinus and to enable guided bone regeneration. Fixation pins (TitanPin, Geistlich) were used when collapse of the barrier membrane was expected and a second barrier membrane (OsteoBiol® *Evolution*, Tecnoss®) was applied on top of the first membrane to allow optimal soft tissue integration. Implants were inserted after the bone grafting procedure. After 6 months after from the implant insertion, all patients received the definitive prostheses and underwent clinical and radiographic examinations. The overall 6-month implant survival rate was 90,9% for zygomatic implants and 100% for auxiliary implants placed in the anterior area and the clinical indicators, such as probing pocket depth, keratinized tissue and plaque and bleeding indices, were good in all patients. The radiographic examinations showed a substantial gain of radiographic bone around the zygomatic implants.

CONCLUSIONS

The findings of this cohort study demonstrate that the proposed "extended sinus elevation technique" to place zygomatic implants in conjunction with sinus bone grafting may decrease the risk of biologic complications, in contrast with traditional zygomatic implant placement, reducing sinus-related symptoms and complications, avoiding the exposure of implant threads in the maxillary antrum and improving biomechanical properties of the prosthesis.

Grafted with

BONE SUBSTITUTE
OsteoBiol® *mp3*®

MEMBRANE
OsteoBiol® *Evolution*

BARRIER -
BONE SUBSTITUTE
OsteoBiol® *Lamina*

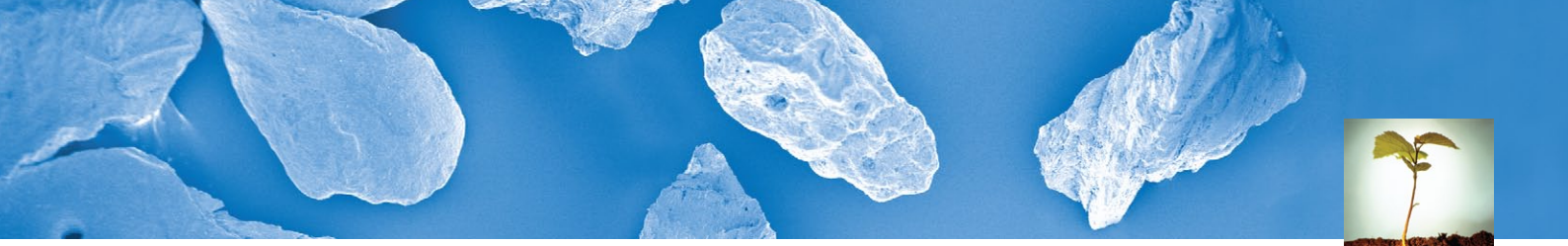

OsteoBiol® by Tecnoss

A 6-month histological analysis on maxillary sinus augmentation with and without use of collagen membranes over the osteotomy window: randomized clinical trial

A Barone[1]
M Ricci[1]
U Covani[1]
RF Grassi[2]
A Quaranta[3]
U Nannmark[4]

1 | Department of Surgery, University of Pisa, Tirrenian Stomatologic Institute, Versilia Hospital, Lido di Camaiore, Italy
2 | Department of Surgery and Dentistry, University of Bari, Bari, Italy
3 | Department of Dentistry, University of Rome "La Sapienza", Rome, Italy
4 | Institute of Biomedicine, The Sahlgrenska Academy Gothenburg University, Gothenburg, Sweden

ABSTRACT

When in the posterior edentulous maxilla the bone volume is insufficient for implant placement, it is necessary to perform a bone augmentation procedure, including the elevation of the sinus membrane from the floor of the maxillary sinus in order to allow the placement of a bone graft. As there are some doubts about the need for using a barrier concurrently with a graft in sinus augmentation procedures, in this randomized clinical trial histological and histomorphometrical analysis were used to assess the effectiveness of the use of a membrane in lateral sinus augmentation procedures, investigating the effect of a resorbable collagen membrane over the osteotomy window on maxillary sinus augmentation healing. After the informed consent was signed, all patients enrolled for this study underwent at least one session of oral hygiene before the sinus elevation procedure. Maxillary sinuses were allocated to either a control (membrane) or test (no membrane) group, using a computerized random allocation process. All the patients were treated with the same surgical technique consisting of sinus floor augmentation via a lateral approach. After the elevation of the sinus membrane, the sinuses were grafted with a mixture of autogenous bone harvested from the lateral bone wall and collagenated cortico-cancellous porcine bone (OsteoBiol® *mp3*®, Tecnoss®, Giaveno, Italy) and the sinuses in the control group were covered with a reabsorbable collagen membrane (OsteoBiol® *Evolution*, Tecnoss®) and the mucoperiosteal flaps were sutured with reabsorbable sutures.
After 6 months and immediately prior to the implant placement, one bone biopsy was harvested from the lateral window and the bone samples were processed and forwarded to the Institute of Biomedicine, the Sahlgrenska Academy Gothenburg University, Sweden for histological examination.

CONCLUSIONS

On the basis of the results of the histological and histomorphometrical analysis, the Authors concluded that compared with sites which were not covered, the use of the membrane may slightly increase the amount of vital bone over a period of 6 months and the use of a membrane seems to reduce the proliferation of the connective tissue and the graft re-absorption rate. Anyway, further studies are needed to explore the advantages of the use of membranes for the sinus augmentation procedure and the influence on the amount and quality of regenerated bone.

ORIGINAL ARTICLE
Clinical Oral Implants Research
2013 Jan; 24(1):1-6

Grafted with

BONE SUBSTITUTE
OsteoBiol® *mp3*®

MEMBRANE
OsteoBiol® *Evolution*

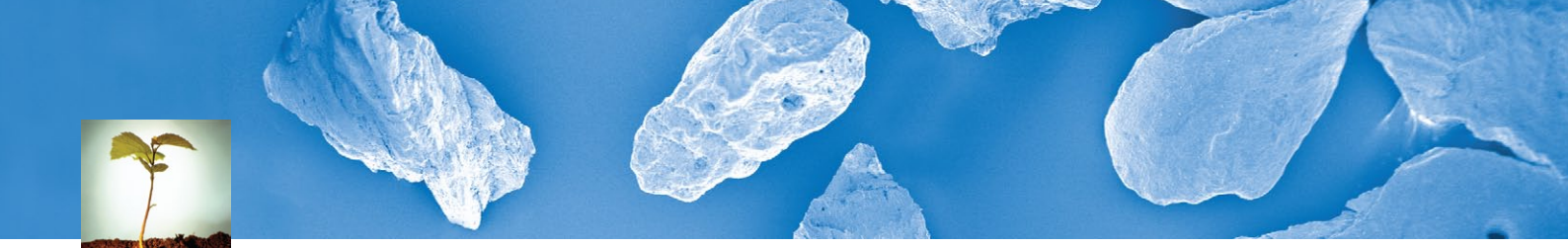

OsteoBiol® by Tecnoss

LATERAL ACCESS SINUS LIFT

051

Ultrastructural study by backscattered electron imaging and elemental microanalysis of bone-to-biomaterial interface and mineral degradation of porcine xenografts used in maxillary sinus floor elevation

MP Ramirez Fernandez[1]
JL Calvo Guirado[1]
JE Maté Sánchez del Val[1]
RA Delgado Ruiz[1]
B Negri[1]
C Barona Dorado[2]

1 | Department of Implant Dentistry, Faculty of Medicine and Dentistry, University of Murcia, Spain
2 | Department of Oral Surgery, Complutense University of Madrid, Madrid, Spain

ORIGINAL ARTICLE
Clinical Oral Implants Research
2013 May;24(5):523-30

ABSTRACT

Adequate alveolar ridges are fundamental to successful rehabilitation with dental implants and different techniques for reconstructing atrophied ridges are available. Bone substitute grafts represent a relevant possibility, provided that the biomaterial for bone substitution is biologically safe and safety depends on the quality of its reproducibility, its biocompatibility, and an absence of toxicity. The aim of this study was to carry out a retrospective investigation of a bone substitute material (BSM) in retrieved bone biopsies from maxillary sinus augmentation in 15 human subjects. The Authors investigated OsteoBiol® *mp3*® (Tecnoss®, Giaveno, Italy), an antigen-free bone consisting 90% porcine granules of dimensions between 600-1000 μm mixed with 10% pure Type-I porcine collagen, used as a bone substitute for sinus augmentation. The investigation was performed by means of an ultrastructural study of the bone-to-biomaterial interface using scanning electron microscopy backscattered electron imaging (SEM-BSE), as well as analysis of the mineral degradation of residual bone substitute graft material using microanalytical system based on energy-dispersive X-ray spectrometry (EDX). In the 15 partially edentulous patients (6 women and 9 men), of ages ranging from 37 to 60 years, the sinus membrane was elevated with curettes of different shapes and after membrane elevation, all sinus cavities were grafted with a BSM. After BSM grafting, an absorbable collagen porcine membrane (OsteoBiol® *Evolution*, Tecnoss®) was placed over the window to minimize soft tissue invasion.
9 months after sinus lifting, bone cores were harvested from the maxillary sinus. The specimens were processed for observation under a SEM-BSE device, then chemical analysis and elemental mapping of the mineral composition were generated using EDX. Scanning electron microscopy revealed that newly formed bone had become closely attached to the xenograft. Elemental analysis (above all, a high Ca/P ratio) showed that there was a gradual diffusion of Ca^+ ions from the biomaterial to the newly formed bone at the interface.

CONCLUSIONS

From a clinical point of view, after a 9-month follow-up period of these 15 patients the success rate was 100%. No perforation of the sinus membrane or other clinical complications such as sinusitis or pain resulted from surgery. The increased volumes produced by the grafting procedures were stable by the end of the healing period and all planned implants could be placed in the augmented sites. The analysis demonstrated that the biomaterial proved to be biocompatible, bioreabsorbable and osteoconductive when used as a bone substitute for maxillary sinus elevation.

Grafted with

BONE SUBSTITUTE
OsteoBiol® *mp3*®

MEMBRANE
OsteoBiol® *Evolution*

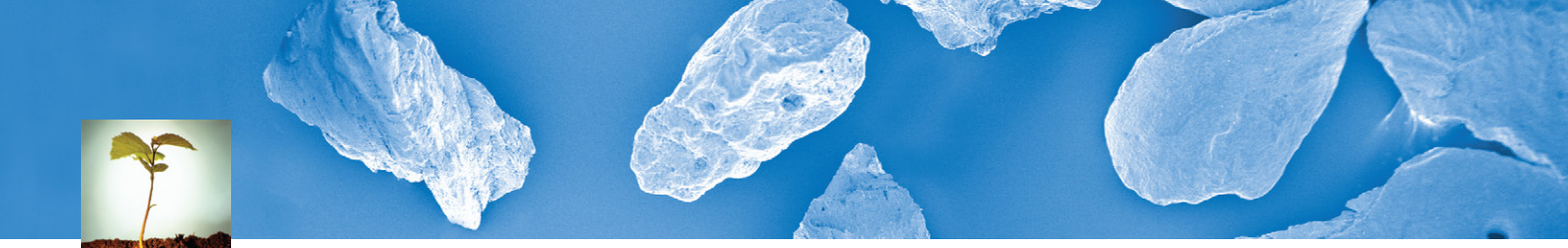

OsteoBiol® by Tecnoss

Simultaneous sinus augmentation with implant placement: histomorphometric comparison of two different grafting materials. A multicenter double-blind prospective randomized controlled clinical trial

M Silvestri[1]
P Martegani[2]
F D'Avenia[3]
M Farneti[4]
D Capri[4]
G Paolantoni[5]
L Landi[6]

1 | Private Practice, Pavia, Italy
2 | Private Practice, Azzate, Italy
3 | University of Parma, Italy
Private Practice, Parma, Italy
4 | Private Practice, Bologna, Italy
5 | Private Practice, Napoli, Italy
6 | Private Practice, Rome, Italy

ORIGINAL ARTICLE
The International Journal of Oral and Maxillofacial Implants
2013 Mar-Apr; 28(2):543-9

ABSTRACT

In many implant treatments, xenogenic biomaterials of different biologic origin are considered to be valid and predictable alternatives to autogenous bone, also for the sinus elevation via the lateral approach for implant rehabilitation of atrophic posterior maxillae.
The aim of the present experimental randomized clinical trial was to evaluate the histologic behavior of two different xenogenic bone substitutes used in sinus floor augmentation procedures via the lateral approach. With a double-blind design, the two bone substitutes tested were a deproteinated particulated bovine bone (DPBB) (Bio-Oss®, Geistlich) and a new grafting material consisting in a particulated cortical porcine bone (PCPB) (OsteoBiol® *mp3*®, Tecnoss®, Giaveno, Italy). In particular, this material has a granulometry ranging from 600 to 1000 μm and the prehydrated form is supplemented with collagen. All patients included in the study were treated with maxillary sinus floor elevation via a lateral approach and one of the two xenografts was used as the sole grafting material. Root-form implants were placed simultaneously. Stage-two surgery was performed at 6 months: all the implants were uncovered and the biopsy specimens harvested from each site, and histomorphometric analyses were performed.

CONCLUSIONS

42 specimen were analyzed histomorphometrically and the results showed no significant differences in total bone volume (PCPB 37.43%, DPBB 37.52%) or residual grafting material (PCPB 13.55%, DPBB 16.44%). As the histomorphometric data presented in the present experimental randomized clinical trial suggest that particulated cortical porcine bone has excellent osteoconductive properties, the Authors concluded that *"in this study, PCPB compared well with DPBB as a grafting material for lateral sinus elevation"*.

Grafted with

BONE SUBSTITUTE
OsteoBiol® *mp3*®

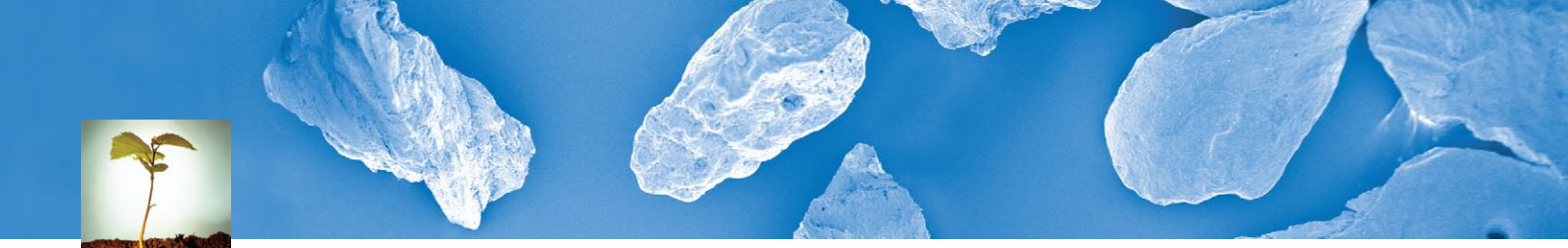

OsteoBiol® by Tecnoss

Histomorphometric outcomes after lateral sinus floor elevation procedure: a systematic review of the literature and meta-analysis

S Corbella[1,2]
S Taschieri[1,2]
R Weinstein[1,2]
M Del Fabbro[1,2]

1 | Department of Biomedical, Surgical and Dental Sciences, Università degli Studi di Milano, Milan, Italy
2 | IRCCS Istituto Ortopedico Galeazzi, Milan, Italy

ORIGINAL ARTICLE
Clinical Oral Implants Research
2016 Sep;27(9):1106-22

ABSTRACT

Very often, the progressive resorption of the alveolar bone caused by tooth loss in the posterior maxilla needs a bone augmentation procedure in order to increase the available bone volume for the placement of dental implants needed to support a fixed prosthetic rehabilitation.
In literature it has been reported that the lateral approach sinus floor elevation (LASFE) can be safely applied in cases of posterior maxilla atrophy, leading to a high implant survival rate.
The aim of the present systematic review of the literature and meta-analysis was to investigate the histomorphometric outcomes of LASFE (Lateral approach sinus floor elevation) surgery in order to evaluate different bone substitute materials (AB, autogenous bone; BB, Bovine bone, AG, allograft; FDBA, freeze-dried bone allograft; HA, hydroxyapatite; PB, porcine bone; PRP, platelet-rich plasma) performances related to new bone formation. After an electronic and manual search, 84 articles were included in the quantitative synthesis and 16 of them in the meta-analysis of comparative studies. Taking into consideration the articles selected, a total of 1846 subjects were treated, and a total of 2224 biopsies were taken and examined. Recorded data were statistically analyzed evaluating percentage of new bone volume, residual biomaterial, and connective/soft tissues in the biopsies. The results show that the use of autogenous bone (AB) alone led to a significantly higher new bone formation if compared with bovine bone (BB) alone ($P = 0.04$), while no significant difference was found when the latter was compared with a mixture of AB and BB ($P = 0.52$). Grafts composed of BB showed significantly greater new bone formation as compared to hydroxyapatite (HA) ($P < 0.001$) while a mixture of tricalcium phosphate (TCP) and HA achieved better outcomes than BB ($P < 0.001$).
PB alone showed at six months a new bone volume range between 31.4% and 43.9%.

CONCLUSIONS

None of the biomaterials used for LASFE procedures demonstrated a significant and predictable superiority regarding new bone formation. The observation that, in comparative studies, the amount of new bone volume was higher for AB than for BB could not be confirmed by clinical results and so it seems that when donor site morbidity is a concern, BB and a mixture of TCP and HA could be considered as predictable alternative with promising results. Anyway, the Authors concluded that *"more randomized, controlled clinical trials providing individual data about the characteristics of the analyzed specimen (size and site of biopsy) and of the residual bone height before intervention may help to achieving a deeper knowledge of the histologic behavior of biomaterials in LASFE procedures"*.

Grafted with

BONE SUBSTITUTE
OsteoBiol® *Apatos*
OsteoBiol® *mp3®*
OsteoBiol® *Gen-Os®*

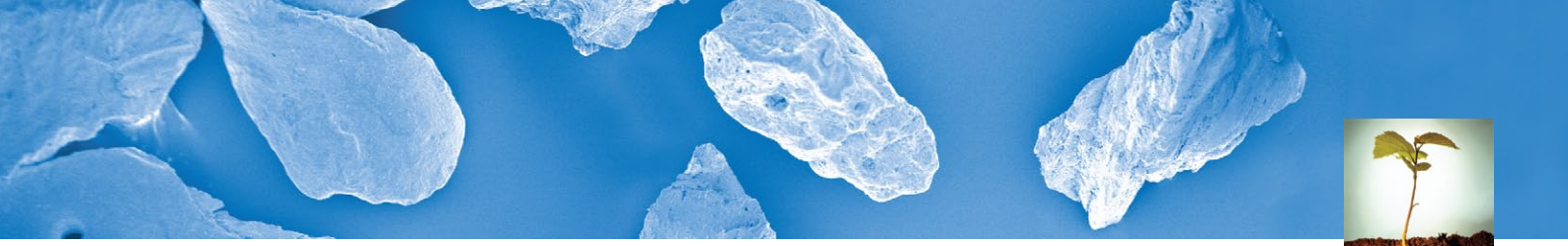

OsteoBiol® by Tecnoss

The use of resorbable heterologous cortical lamina as a new sinus lift floor: a technical note

M A Lopez[1]
N Manzulli[2]
M Casale[3]
Z Ormianer[4]
F Carinci[5]

1 | Private practice in Rome, Italy
2 | Private practice in Cerignola, Foggia, Italy
3 | Policlinico Universitario Campus Biomedico, Rome, Italy
4 | Department of Oral Rehabilitation, Tel-Aviv University, Tel-Aviv, Israel
5 | Department of Morphology, Surgery and Experimental Medicine, University of Ferrara, Ferrara, Italy

ABSTRACT

In case of necessity of a pre-implant bone regeneration by mean of a grafted biomaterial, it is necessary that such biomaterial remains stable *in situ*, without micro movements, for about six months. Some of these biomaterials, such as pre-hydrated and collagenated cortico-cancellous porcine bone granules promote the formation of good-quality new bone. Unfortunately, they do not have the mechanical characteristics that would allow for stability in terms of shape and size. On the contrary, some grafting materials, such as heterologous porcine cortical lamina, have an excellent capacity in creating recipient sites that can be filled with cortico-spongious collagenated bone paste that reabsorbs, promoting new bone formation.

In this technical note, the Authors propose a technique for the reconstruction of a new rigid artificial sinus floor with the use of resorbable biomaterials of porcine origin: a cortical lamina in connection with pre-hydrated and collagenated cortico-cancellous porcine bone. The prerequisites necessary to carry out the technique are the stability of the lamina and the presence of a sufficient amount of graft granules in the site. For this technique, a rigid porcine cortical lamina was modelled and positioned in the sinus as a new sinus floor without hydration (OsteoBiol® *Lamina*, Tecnoss®, Giaveno, Italy). A pre-hydrated and collagenated cortico-cancellous porcine bone was used as filler in the new space created by OsteoBiol® *Lamina*, palatal wall, mesial and distal bone (OsteoBiol® *mp3*®, Tecnoss®). A porcine resorbable membrane was used to cover the graft in the vestibular side (OsteoBiol® *Evolution*, Tecnoss®).

CONCLUSIONS

The adequate vascularisation of the graft combined with the integration of the lamina, which does not need to be removed, makes possible to propose this technique as a potential alternative to those used so far. The Authors conclude: *"In our experience, it is possible to propose this technique as an alternative to those previously and currently in use. Additional clinical and histological scientific studies are needed to evaluate the effectiveness of the technique and further develop its potential"*.

ORIGINAL ARTICLE
Journal of Biological Regulators and Homeostatic Agents
2016 Apr-Jun;30(2 Suppl 1):75-79

Grafted with

BONE SUBSTITUTES
OsteoBiol® *mp3*®

MEMBRANE
OsteoBiol® *Evolution*

BARRIER - BONE SUBSTITUTE
OsteoBiol® *Lamina*

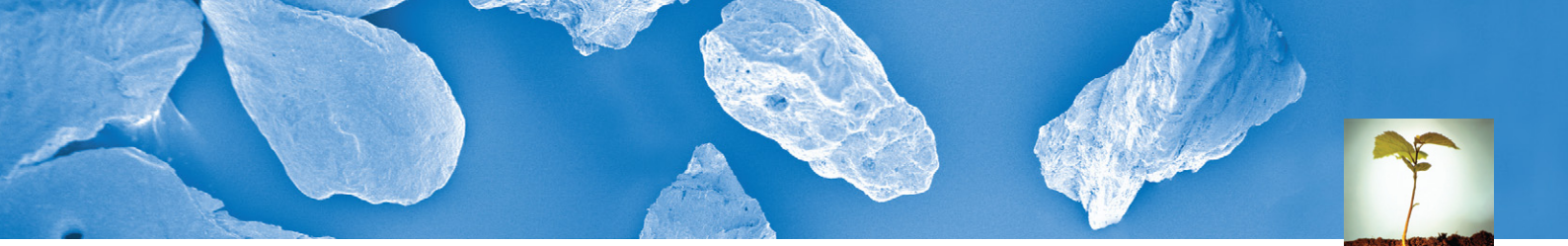

OsteoBiol® by Tecnoss

Immediately loaded zygomatic implants vs conventional dental implants in augmented atrophic maxillae: 4 months post-loading results from a multicentre randomised controlled trial

M Esposito[1]
R Davó[2]
C Marti-Pages[3]
A Ferrer-Fuertes[3]
C Barausse[4]
R Pistilli[5]
DR Ippolito[6]
P Felice[4]

1 | Department of Biomaterials, The Sahlgrenska Academy at Göteborg University, Sweden
2 | Department of Implantology and Maxillofacial Surgery, Medimar International Hospital, Alicante, and Hospital Clinic, Barcelona, Spain
3 | Oral and Maxillo- facial Surgery Unit, Hospital Clinic, Barcelona, Spain
4 | Department of Biomedical and Neuromotor Sciences, Unit of Periodontology and Implantology, University of Bologna, Bologna, Italy
5 | Oral and Maxillo- facial Unit, San Camillo Hospital, Rome, Italy
6| Department of Biomedical and Neuromotor Sciences, Unit of Orthodontics, University of Bologna, Bologna, Italy

ORIGINAL ARTICLE
European Journal Of Oral Implantology
2018;11(1):11-28

ABSTRACT

The presence of insufficient bone volume can limit dental implants placement and so several bone augmentation procedures with different grafting materials have been developed, in order to allow a correct implant anchorage. In case of severely atrophic maxillae, zygomatic implants can be an alternative to conventional bone augmentation and implant rehabilitation. The aim of this randomised controlled trial (RCT) of parallel group design was to compare the clinical outcome of immediately loaded cross-arch maxillary prostheses supported by zygomatic implants vs conventional implants placed in augmented bone. Patients with totally edentulous atrophic maxillae were randomly allocated to bone augmentation with a bone substitute and six to eight conventionally loaded dental implants (augmentation group) or four zygomatic implants, or two zygomatic and two conventional implants to be immediately loaded (zygomatic group). In the augmentation group, collagenated blocks (OsteoBiol® *Sp-Block*, Tecnoss®, Giaveno, Italy) of equine cancellous bone were used as onlays/veneers. The blocks were hydrated before use for 5 to 10 min with sterile, lukewarm physiological solution or with antibiotics. Afterwards, they were modelled to be adapted to the receiving site. To fill the gaps between the recipient bone and the bone blocks, OsteoBiol® *mp3®* bone substitute granules were used. Small defects could only be grafted with bone substitute granules according to clinical indications and the surgeon's preference. Nasal sinus lift procedures using OsteoBiol® *mp3®* bone substitute granules could also be implemented. All the grafted areas and the maxillary windows were covered with OsteoBiol® *Evolution* resorbable barriers from equine pericardium. After implant insertion, the surgeon was allowed to cover exposed implant threads using a paste made of 600 micron to 1000 micron pre-hydrated collagenated cortico-cancellous granules of porcine origin, mixed with OsteoBiol® *Gel 0* in sterile syringe (OsteoBiol® *mp3®*, 1 cc, Tecnoss®) and resorbable collagen barriers (OsteoBiol® *Evolution*, Tecnoss®). Patients were followed up to 4 months after loading, in order to measure outcomes related to prosthesis, implant and augmentation failures, any complications, quality of life (OHIP-14), the number of days that patients experienced total or partial impaired activity, time to function, and number of dental visits. No augmentation procedure failed. Preliminary 4-months post-loading data suggest that zygomatic implants were associated with statistically significantly less prosthetic and implant failures, as well as time needed to functional loading when compared with augmentation procedures and conventionally loaded dental implants. More complications were reported for zygomatic implants, which were solved spontaneously or could be handled.

CONCLUSIONS

Keeping in mind that placement of zygomatic implants is a complex procedure requiring skilled and experienced operators, zygomatic implants proved to be a better rehabilitation modality for severely atrophic maxillae. Anyway, long-term data are essential to confirm or dispute these preliminary results.

Grafted with

BONE SUBSTITUTES
OsteoBiol® *mp3®*
OsteoBiol® *Sp-Block*

MEMBRANE
OsteoBiol® *Evolution*

PAG 113

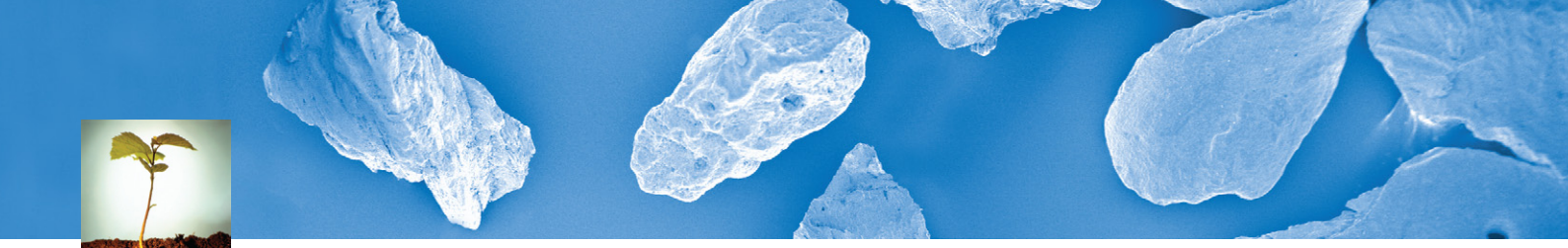

OsteoBiol® by Tecnoss

Immediately loaded zygomatic implants vs conventional dental implants in augmented atrophic maxillae: 1-year post-loading results from a multicentre randomised controlled trial

R Davó[1,4]
P Felice[2]
R Pistilli[3]
C Barausse[2]
C Marti-Pages[4]
A Ferrer-Fuertes[4]
DR Ippolito[2]
M Esposito[5]

1 | Department of Implantology and Maxillofacial Surgery, Medimar International Hospital, Alicante, Spain
2 | Department of Biomedical and Neuromotor Sciences, Unit of Periodontology and Implantology, University of Bologna, Bologna, Italy
3 | San Camillo Hospital, Rome, Italy
4 | Hospital Clinic, Barcelona, Spain
5 | Department of Biomaterials, The Sahlgrenska Academy at Göteborg University, Sweden

ORIGINAL ARTICLE
European Journal Of Oral Implantology
2018;11(1):145-161

ABSTRACT

The presence of insufficient bone volume can limit dental implants placement and so several bone augmentation procedures with different grafting materials have been developed in order to allow a correct implant anchorage. In case of severely atrophic maxillae, zygomatic implants can be an alternative to conventional bone augmentation and implant rehabilitation. The aim of this randomised controlled trial (RCT) of parallel group design was to compare the clinical outcome of immediately loaded cross-arch maxillary prostheses supported by zygomatic implants vs conventional implants placed in augmented bone. Patients with totally edentulous atrophic maxillae were randomly allocated to bone augmentation with a bone substitute and six to eight conventionally loaded dental implants (augmentation group), or to receive four zygomatic implants, or two zygomatic and two conventional implants to be immediately loaded (zygomatic group). In the augmentation group, collagenated blocks (OsteoBiol® *Sp-Block*, Tecnoss®, Giaveno, Italy) of equine cancellous bone were used as onlays. To fill the gaps between the recipient bone and the bone blocks, OsteoBiol® *mp3*® bone substitute granules were used. All the grafted areas and the maxillary windows were covered with OsteoBiol® *Evolution* resorbable barriers from equine pericardium. After implant insertion, the surgeon was allowed to cover exposed implant threads using (OsteoBiol® *mp3*®, Tecnoss®) and resorbable collagen barriers (OsteoBiol *Evolution*, Tecnoss®). Patients were followed up to 1 year after loading. No augmentation procedure failed. Five patients dropped out from the augmentation group. Six prostheses could not be delivered or failed in the augmentation group vs one prosthesis in the zygomatic group, with a statistically significant difference. Eight patients lost 35 implants in the augmentation group vs two patients who lost four zygomatic implants, with a statistically significant difference. A total of 14 augmented patients were affected by 22 complications vs 28 zygomatic patients (40 complications), the difference being statistically significant. Both groups had significantly improved quality of life (OHIP-14) scores.

CONCLUSIONS

Based on the results, Authors concluded that *"preliminary 1-year post-loading data suggest that immediately loaded zygomatic implants were associated with statistically significantly fewer prosthetic failures (one vs six patients), implant failures (two vs eight patients) and time needed to functional loading (1.3 days vs 444.3 days) when compared to augmentation procedures and conventionally loaded dental implants. Even if more complications were reported for zygomatic implants, they proved to be a better rehabilitation modality for severely atrophic maxillae. Long-term data are absolutely needed to confirm or dispute these preliminary results"*.

Grafted with

BONE SUBSTITUTES
OsteoBiol® *mp3*®
OsteoBiol® *Sp-Block*

MEMBRANE
OsteoBiol® *Evolution*